UCSF Surgical Department

Client: Dr. Hobart Harris

Detail Packet

Deliverable #1B

Biodesign Immersion Experience 2014

Professor A.E. Herr

June 17, June 20, June 24, and June 26

Team Members		
Gold Team	**Blue Team**	**Oski Team**
Adrian Tabula	Helen Sun	Vinay Viswanadham
Suzanne Chou	Derek Liu	Toan Nguyen
Lakshmisahithi Rani	Vivian Shen	

I. DISEASE STATE FUNDAMENTALS

A. Anatomy and Physiology

Digestive System Overview:

The digestive system is made up of the liver, pancreas, gallbladder (the solid organs), and the hollow gastrointestinal (GI) tract, or digestive tract, which consists of the mouth, esophagus, stomach, small intestine, large intestine, and anus, as you can see in Figure 1. It works together with parts of the nervous system and circulatory system to digest the foods and liquids that the body consumes each day. This digestion allows the body to break down food into nutrients and then into protein, carbohydrates, fat, and vitamins, which provide energy to the body for growth and repair.

The path food and liquid take through the GI tract starts with the mouth, where it is chewed and mixed with saliva, then sent to the esophagus via swallowing. It then passes through the lower esophageal sphincter into the upper part of the stomach, where food and liquid are stored and then mixed in the lower part of the stomach with its own digestive juices and acid. The stomach then slowly releases its contents, now called chyme, into the small intestine, where it is mixed with more digestive juices from the liver, the pancreas, and the small intestine. Through peristalsis in the small intestine, which is the muscle movement of the organ walls, chyme is pushed toward the large intestine while the walls of the small intestine absorb nutrients from the chyme into the bloodstream, where the nutrients are distributed to the rest of the body via the bloodstream. This leaves mainly waste products of undigested food and older cells from the GI tract lining to be pushed into the large intestine, which absorbs water and any remaining nutrients from the waste. The large intestine also changes the waste into stool, which is then stored in the rectum until a bowel movement pushes it out through the anus.[1]

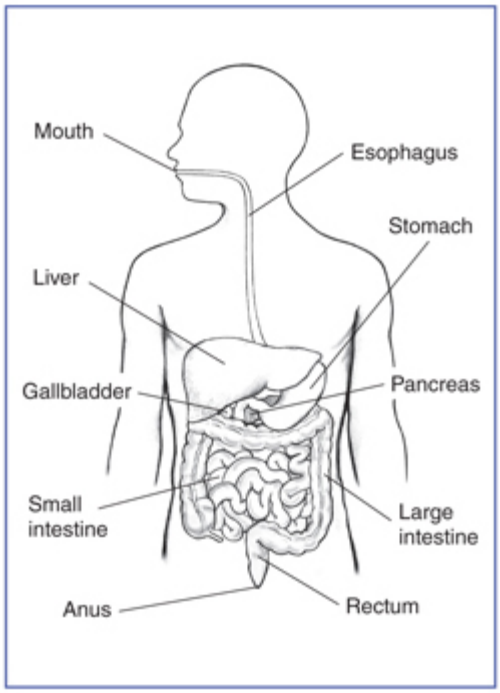

Figure 1: The digestive system. [1]

Stomach:

The stomach is where digestion of the food bolus begins. Food enters from the esophagus through the lower esophageal sphincter and exits through the pyloric sphincter into the small intestine, as can be seen in Figure 2.

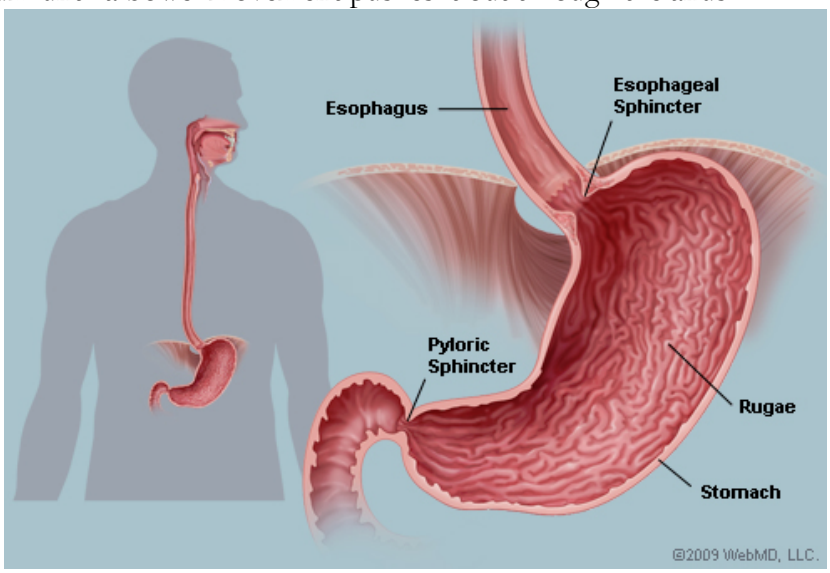

Figure 2: The J shape of the stomach can be seen, as well as the overall anatomy.

The stomach has three

layers of muscle that contract periodically to aid in digestion by churning the food bolus.[3] The three layers are circular, longitudinal, and oblique, each of which are made up of smooth muscle layers. The longitudinal layer is continued from the esophagus. The circular layer is around the middle portion (the main body) of the stomach, and the oblique layer is the innermost layer of the muscle. On the periphery of the muscle layers is the serosa layer, which is made up of simple squamous epithelium. Most of the vasculature is located in this layer of the stomach. The submucosa is the connective tissue layer inside the muscle layer, which connects the muscle to the mucosa layer. The innermost layer of the stomach is the mucosa layer, which is made up of smooth muscle, connective tissue, and the specialized cells of the stomach.[4] Once the food bolus leaves the stomach, it is now referred to as chyme. Once the chyme leaves the stomach, there are folds in the stomach called rugae. These folds expand to allow for new food to enter, therefore increasing the volume of the stomach to 1.5 gallons.

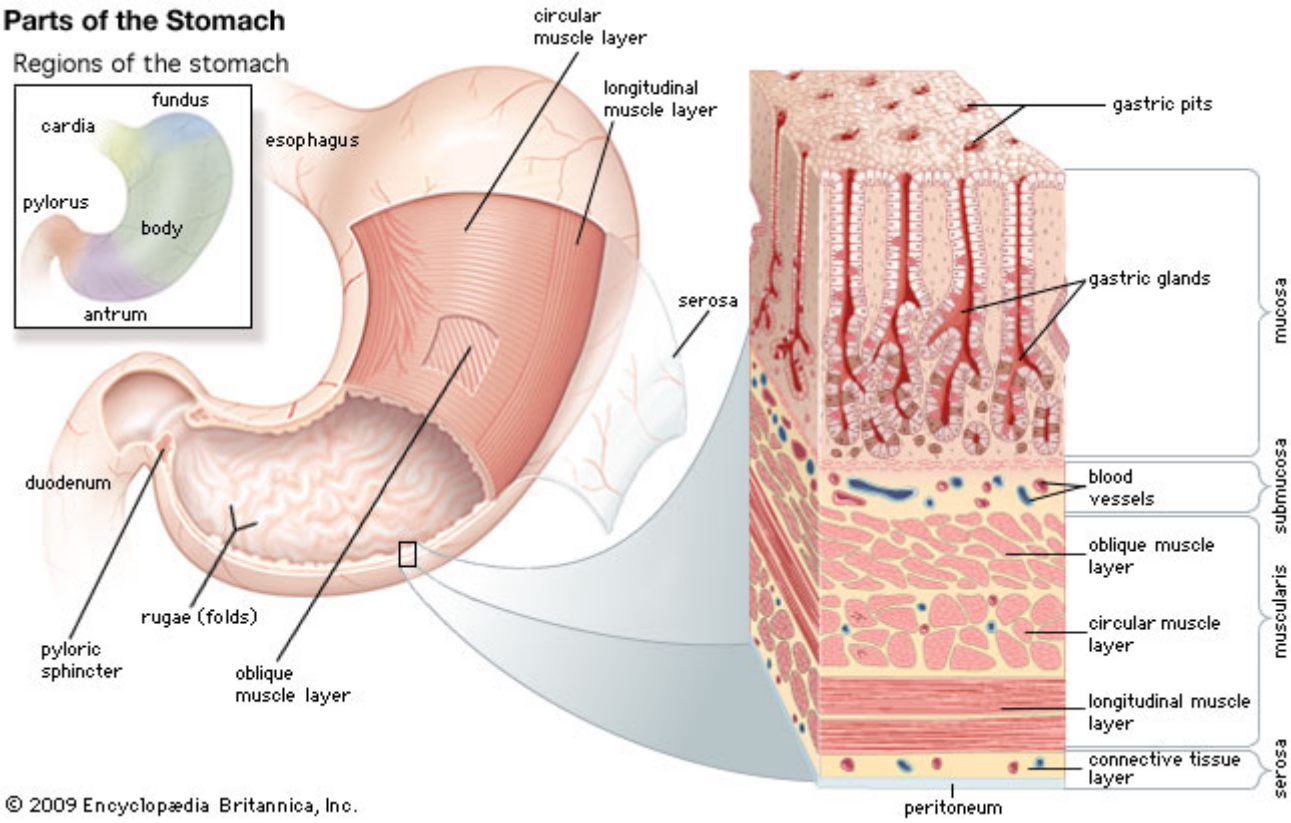

Figure 3: The various muscle layers can be seen: circular, longitudinal, and oblique. In addition, the regions of the stomach are shown in the upper left corner. The fundus is the top portion, the body is the main portion, and the antrum which is the lower portion. In addition, the various layers (mucosa, serosa, etc.) can be seen in the right. [5]

There are various types of cells in the stomach that help with digestion: chief cells, parietal cells, and G cells . The chief cells are responsible for secreting proteases such as pepsinogen, which is the inactive zymogen to pepsin. This conversion is activated by the acidic environment (ideally pH 1.5-2.5) of the stomach, which consequently allows for protein digestion.[6]

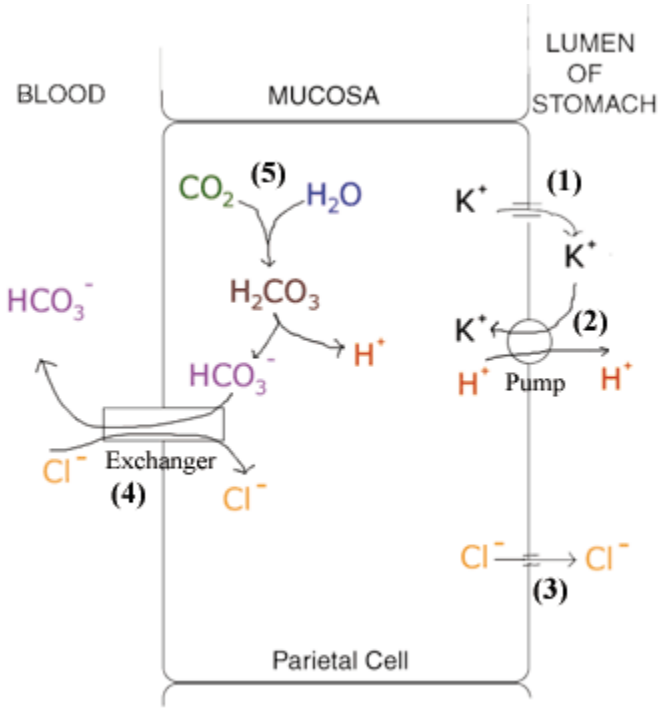

Figure 4: The parietal cells in the stomach provide H^+ and Cl^- separately, creating the acidic environment that the stomach thrives in.[7]

Parietal cells are responsible for secreting hydrochloric acid (HCl) into the lumen, and provide the acidic environment that the stomach is so well known for. In addition to activating pepsin, the acidic environment also serves to eliminate any unwanted bacteria that may have been accidentally ingested. As shown in Figure 4, the parietal cell mainly works through a H^+/K^+ ATPase pump that interfaces with the stomach lumen as well as a HCO_3^-/Cl^- pump that exchanges ions with the bloodstream.

G cells secrete the gastric juices, which also aids in creating the acidic environment in the stomach.[8] Once food enters the stomach, it stimulates the release of the hormone gastrin, which then signals to the G cells to release the gastric juices. Gastrin also aids in the motility of the stomach.[9]

In addition, there are mucous cells which line the epithelium of the stomach and protect it from the acidic juices. These cells secrete a bicarbonate-rich mucus that lines the lumen and lubricates the surface.

Liver:

The liver weighs in around 3 pounds and resides on the right side of the body, below the ribs. It is divided into 2 main lobes of unequal size (left and right). Both lobes have many lobules, each made of hepatocytes which monitor, add, and remove substances from the blood flowing by. This blood is brought in by two main vessels. The hepatic artery brings oxygen-rich blood from the heart to the liver, while the portal vein brings nutrient-rich blood from the small intestine to the liver. These vessels divide smaller and smaller until they are capillaries extending to each lobule as seen in Figure 5. The hepatic vein brings filtered blood from the liver back to the heart which distributes it out to the rest of the body.

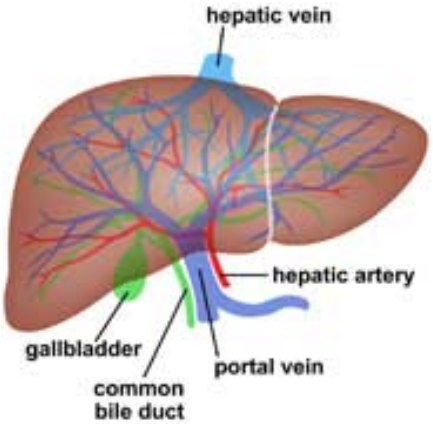

Figure 5: Liver anatomy[10]

The liver has several key functions that help the body stay healthy. One important function of the liver is removing and excreting body wastes, hormones, drugs and other foreign substances. Enzymes in the liver alter some toxins so they can be more easily excreted in urine. Another important liver function is synthesizing plasma proteins, including the majority of those necessary for blood clotting like fibrogen. Other important plasma proteins synthesized in the liver include albumin, which binds many water-insoluble substances and contributes to osmotic pressure, and certain globulins which transport substances such as cholesterol and iron. Another key function of the liver is producing immune factors and removing

bacteria, which helps the body fight infection. The phagocytes in the liver produce proteins in response to microbes, which helps with the inflammation process, tissue repair, and immune cell activities.

The liver takes on many other roles that allow the body to run smoothly. For example, it continuously secretes bile to aid in digestion and absorption, which is then stored in the gallbladder until a meal, when bile enters the beginning of the small intestine. The liver also excretes bilirubin, which is one of the few waste products in bile. Macrophages in the liver remove worn out red blood cells from the blood. Bilirubin then results from the breakdown of the hemoglobin in the red blood cells and is excreted into the bile by hepatocytes. The liver also processes nutrients absorbed from the digestive tract like fatty acids and stores certain vitamins like A,D,K, and B12, minerals like iron and copper, and sugars like glycogen. The liver also has the notable ability to self-repair and regenerate damaged tissues. This is important to its function because liver damage can occur simply from its exposure to harmful substances during toxin clearing. A failing liver might also regenerate and allow the patient to survive and regain a normal life, if it is supported for some time.[11]

Gall Bladder (and Biliary Duct):

The gallbladder is a small sac-like organ located dorsally to the liver on the right side of the abdomen. Its primary purpose is to store and concentrate the bile made by the liver. Typically, 50% of the bile produced is stored in the gallbladder. Because it is hollow, its size changes depending on the activity of the digestive system: prior to a meal it may be filled with bile and about the size of a small pear, while after a meal it may deflate to become empty and flat.[12]

The common bile duct is the conduit between bile in the gallbladder and the duodenum of the small intestine. Figure 6 below shows the junction of the cystic duct and the common hepatic duct into the common bile duct.[13] In the duodenal wall is the connection between the common duct and the pancreatic duct, the ampulla of Vater.

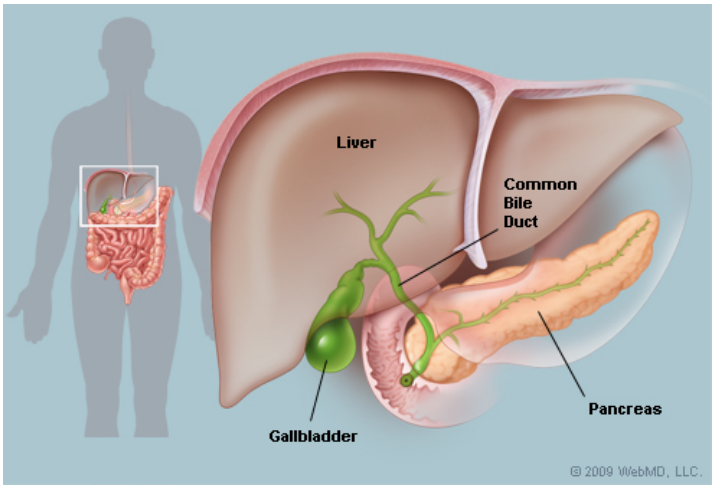

Fig 6. The gallbladder and associated connections (green) in relation to other abdominal organs.[12]

Regulation of bile release into the small intestine during digestion is regulated by the sphincter of Oddi, located at the ampulla of Vater at the duodenal papilla. When contracted (during periods between digestion), the sphincter of Oddi blocks bile release into the duodenum and builds pressure in the common bile duct, causing bile to flow instead into the gallbladder

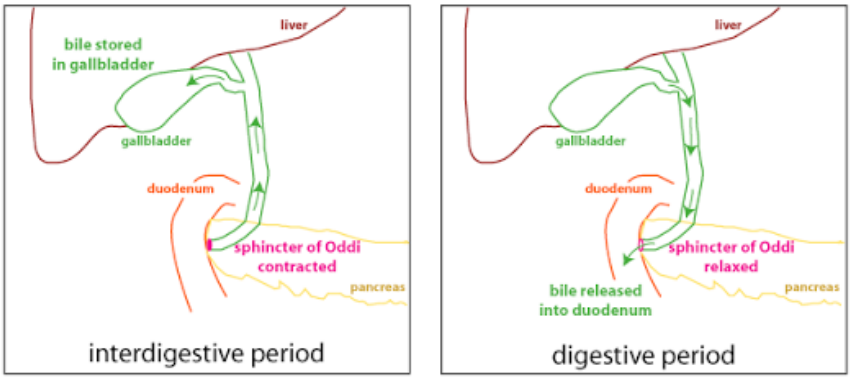

Fig. 7: Mechanism of action for bile release.[14]

(Figure 7). Epithelial cells in the gallbladder concentrate the bile by reabsorbing water and electrolytes [B]. When fatty acids are detected in the duodenum, endocrine cells release cholecystokinin (CCK) and stimulate both the smooth muscle cells of the gallbladder to contract and the sphincter of Oddi to relax. Bile then flows freely into the duodenum.

Pancreas:

The pancreas is a pear-shaped organ, approximately 6 inches long, located behind the stomach and just under the liver (Figure 6).[15] The wider end, the head, is towards the middle of the abdomen, while the more narrow neck, body, and tail extend to the left. Blood is supplied to the pancreas via the superior mesenteric artery and vein, the portal vein, and the celiac artery. The pancreas is connected to the small intestine via the pancreatic duct, which joins the common biliary duct and empties into the duodenum.[16]

The pancreatic has both exocrine and endocrine functions. Islet cells in the pancreas are responsible for the production of both insulin and glucagon, the two major pancreatic hormones.[16] Insulin causes glucose uptake by muscle, red blood, and fat cells, lowering blood glucose levels. Glucagon does the opposite, raising blood glucose levels by causing the liver to release glucose.

The pancreas' exocrine function consists mainly of digestive juices. It secretes an alkaline fluid that contains both active enzymes and zymogens, which are inactive precursors that are activated in the small intestine.[17] These proteins help in the breakdown of fats, carbohydrates, and proteins.[16] The pancreas secretes about 1.5 litres of digestive fluids a day.[17]

Small Intestine:

The small intestine is a hollow, tube-like organ that connects to the stomach on one end and the large intestine on the other end. It is the longest part of the gastrointestinal tract and is about 6 meters, or 20 feet long in adult humans. The small intestine is divided into three sections, called the duodenum, jejunum, and the ileum. The diameter of the small intestine is only about one inch, but is responsible for absorbing about 90% of the nutrients from the food consumed.[18,19] The small intestine and its surrounding organs.

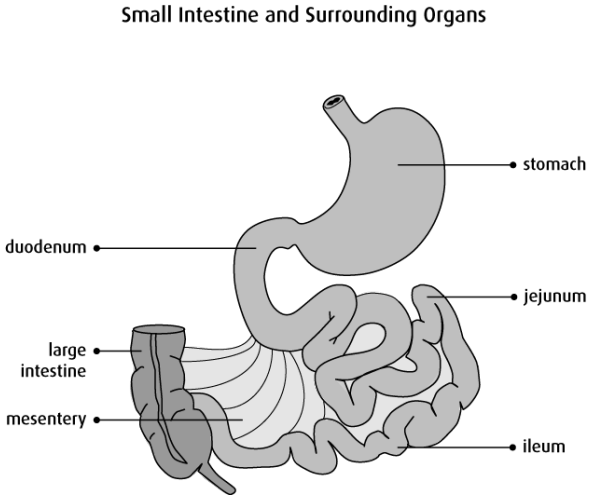

Figure 8: The small intestine and its surrounding organs.[20]

The duodenum is the first portion of the small intestine and has a C-shape that loops around the front of the kidney and upper lumbar vertebrae. The duodenum takes partially digested food and enzymes from the stomach and pancreas and begins the absorption of some nutrients. Duodenal enterocytes absorb ferric and heme iron, needed for hemoglobin production. The duodenum also absorbs calcium using active transport proteins. Most other nutrients from food however, are absorbed in latter parts of the small intestine. The duodenojejunal flexure joins the duodenum and the jejunum.[19,21]The jejunum is the middle region of the small intestine. In most adults, the jejunum is around 2.3-3 meters long. The jejunum is suspended by mesentery, which gives it the ability to move within the abdomen. The internal structure of the jejunum, a mucous membrane, is covered in villi to aid with absorption of nutrients. These villi also contain microvilli, to increase the surface area in which absorption can occur. The

villus is made up of two types of epithelial cells. These are absorptive cells called enterocytes and goblet cells that secrete mucous.[19,22]

The ileum was the longest segment of the small intestine. It is about 4 meters in length and extends from the jejunum and empties into the large intestine. The peristaltic contractions that occur in the small intestine are slower in the ileum and the smooth muscle in the area is thinner. The terminal ileum is responsible for absorbing vitamin B12 and conjugated bile salts. [19,24]

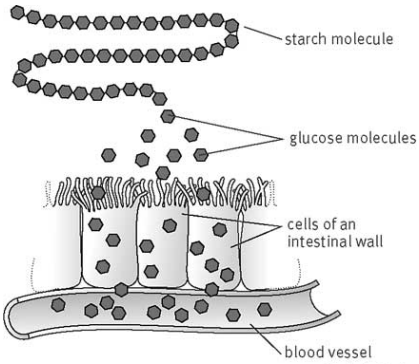

Figure 9: The small intestinal walls are responsible for absorbing nutrients through villi and microvilli.[23]

Large Intestine:

The colon has three fundamental functions: pass digested matter out of the small intestine to the rectum, promote reabsorption of water and fat-soluble vitamins from digested matter, and support a diverse intestinal bacterial community (the microflora) that feeds on the digested matter. The colon stretches from the end of the small intestine (the ileum) to the rectum, which eventually stores and passes feces out of the body. Feces contain some substances that the body could not digest as well as several bacteria from the intestine. Several blood vessels wrap around the colon for its absorptive purposes; bleeding of colorectal vasculature can lead to necrosis of colorectal tissue. Other pathologies of the colon include colorectal cancer and inflammatory bowel diseases (due to immune attack on the bowel or bacterial attack) can also pose complications to the colon's function. Pathogenesis of the colon can compromise the ability to pass feces and can lead to severe infection in the lower abdomen. In these cases, surgeons may need to remove diseased regions of the colon (either partial or full colectomy). Afterward, either healthy regions of the colon are joined together or a colostomy is formed, in which the end of the bowel still connected to the main GI tract is shaped into a stoma, which empties out into a pouch that hangs from the skin and must be periodically cleaned and replaced.

B. Pathophysiology, Clinical Presentation, Clinical Outcome, Epidemiology

Abdominal and inguinal hernias:

A ventral hernia results from weakness in the anterior abdominal wall that can result in tissue and organs, particularly the intestines, bulging out through the abdominal wall. Some ventral hernias result from incompletely healed surgical wounds; if the incision does not completely heal, then the organs can bulge through. In a similar fashion, an inguinal hernia involves tissue or organ bulging through a weakness of the abdominal cavity into the inguinal canal. The spermatic cords (the vas deferens and circumferential tissue) in males and the round ligaments (which joins the uterine horns to the labia) in females run through the inguinal canal. Treatment of each of these types of hernia, therefore, involves relocation of the bulging mass into the appropriate cavity and strengthening of the cavity wall with extra suturing or with an implantable mesh.

Colon Cancer:

Colorectal cancers affect both the colon and the rectum (the last few inches of the colon where feces is stored and excreted from). While the direct causes of colorectal cancer are still

unknown, tumors can develop from small benign polyps that initially pose few, if any, symptoms. Periodic colonoscopies past the age of fifty, therefore, are encouraged to search for such polyps and target them for removal. Symptoms of colorectal cancer include changes in bowel behaviors, rectal bleeding, fatigue, and weight loss.[25]

Colorectal cancers arise from the large intestine epithelium. While genetics plays a part in the development of colon cancer, other health conditions and environmental factors play significant roles, such as diabetes and obesity, consumption of red meat, age, inflammation in the colon, problems with the gut microbiota, smoking and alcohol, and a sedentary lifestyle.[26] The majority of colorectal tumors arise from adenomas, which contribute significantly to tumor malignancy along with location of the tumor and. Adenomatous cells are histologically characterized by cigar-shaped nuclei with excess amounts of chromatin and by cells arranged in a palisade conformation (narrow cells closely packed). Colorectal tumors arise from polyps, which can be either hyperplastic (almost always benign) or neoplastic (of which adenomatous polyps are a part and have malignant potential). As polyps are excessive growths of colorectal epithelium, the evolution of certain polyps into malignant tumors involves the loss of molecular controls over growth and differentiation.[27]

Defects in cell growth and differentiation control pathways lead to polyp cells rapidly proliferating and becoming carcinogenic. Defects in the canonical Wnt signaling pathway, for example, have been implicated in malignancies of colorectal tumors. The canonical Wnt signaling pathway controls cell differentiation; a major downstream effector of the Wnt pathway is beta-catenin. The CTNNB1 gene codes for beta-catenin, which accumulates in the cell nucleus when stabilized and binds to TCF transcriptional co-factors in order to initiate the expression of various genes that promote differentiation and proliferation.[28] Without Wnt signaling through the Fz cell surface receptor (a member of the class of G-protein coupled receptors), beta-catenins are targeted for destruction. A complex comprising of phosphorylates Axin, APC (adenomatosis polyposis coli), protein phosphatase 2A (PP2A), glycogen synthase kinase 3 (GSK3) and casein kinase 1□ (CK1□) forms to bind beta-catenin and add a ubiquitinin sequence to it, marking it for export to a proteasome for degradation.[29] However, Wnt binding to Fz translocates the destruction complex to the cytoplasmic face of the cell surface, and a negative regulator of Axin dephosphorylates it for deactivation. Thus, beta-catenins are allowed to accumulate in the nucleus to bind to TCFs, leading to near-constitutive expression of growth and differentiation genes.

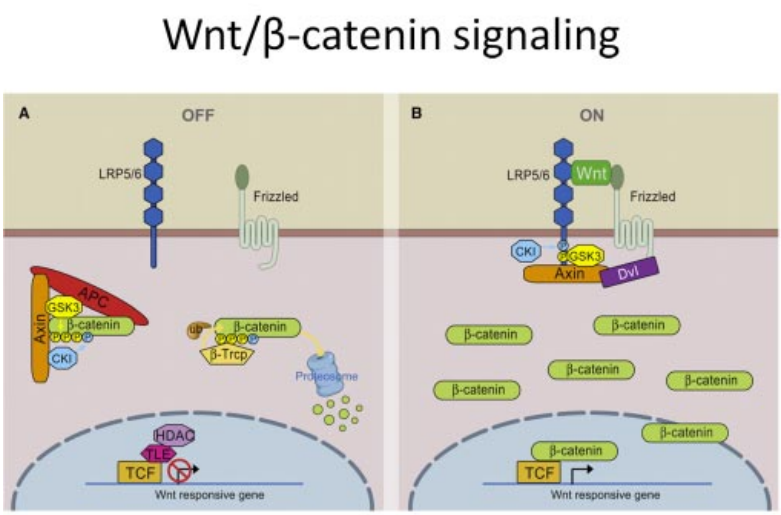

Figure 10: Wnt/B-catenin signaling[30] McDonald et al., *Dev Cell*. 2009 Jul;17(1):9-26.

In colorectal tumors, the genes encoding beta-catenin and some of its upstream regulators are proto-oncogenes. Overexpression of these components or mutations that render them insensitive to deactivation can lead to excessive beta-catenin buildup. APC and axin function as tumor suppressors in that they suppress the activity of stimulatory beta-catenins. Additionally, some members of the TCF family suppress the formation of the beta-catenin/TCF complex that leads to

gene activation. In many colorectal cancer tumors, mutations in APC, APC analogues, and beta-catenin are most common; germline mutations of APC can result in hereditary colorectal cancers. Mutations in the tumor suppressor gene p53 can also lead to invasive adenomas, since the p53 protein regulates the cell cycle of intestinal epithelial cells and kills off Wnt-defective cells.[31]

Mutations can arise due to germline inheritance (in which mutations in proto-oncogenes or tumor suppressor genes are inherited) or somatic mutation. In particular, somatic mutations can result from defects in DNA repair mechanisms due to mutations in DNA repair genes or epigenetic effects upon DNA repair machinery. In recent years, the term "field cancerization"[32] describes how certain patches of tissue within the colon bear a genomic and epigenomic profile conducive to oncogenesis. Current research aims to identify the myriad epigenetic changes that support cancer growth.

Colorectal tumors can vary in their states of differentiation; however, malignant tumors spread within the colon. The TNM classification system for solid tumors describes the stage of the colorectal cancer based on the size of tumors and their spread past the site of origin.[33] "T" describes the size or extent of the primary tumor, "N" the degree of spread to local lymph nodes involved, and "M" the presence of distant metastasis (either no metastasis or the cancer has metastasized past regional lymph nodes). Combinations of TNM values correspond to distinct stages, from Stage I (tumor confined to the mucosa of the small intestine) to Stage IV (cancer has distantly metastasized, with varying degrees of T and N values). Colon cancers spread when tumors penetrate the wall and their cells enter the bloodstream, allowing tumors to arise in local lymph nodes such as the Peyer's patches and take root in other GI organs such as the liver. Recent research has shown that the genetic potential for colorectal tumors to metastasize exists early on in the life cycle of an adenomatous intestinal epithelial cell.[34]

Obesity (as a qualification for surgery):

As obesity prevalences rise in the U.S. to over 20% of the population[--], bariatric, or weight-loss, surgeries like gastric bypass seem more appealing. However, there are several medical guidelines that need to be met in order to qualify for gastric bypass. Because these surgeries come with their own risks, the potential health benefits must outweigh these risks for the surgery to be deemed appropriate. These guidelines include unsuccessful efforts to lose weight with diet and exercise, a body mass index (BMI) of 40 or higher (extreme obesity), or a BMI of 35 to 39.9 (obesity) with serious weight-related health problems, such as type 2 diabetes, high blood pressure or severe sleep apnea. In some cases, patients may qualify for certain types of weight-loss surgery if their BMI is 30 to 34 and they have serious weight-related health problems.[35]

Obesity takes a role in the pathophysiology of type 2 diabetes through several mechanisms such as by escalating the development of insulin resistance. Excess adipose tissue increases the amount of chronic circulating fatty acids which reduces the usage of glucose as a source of cellular energy. These fatty acids deposit more fat in the muscles and liver and generate more metabolites like ceramide and diacylglycerol. These metabolites then activate isoforms of protein kinase C that impede insulin signalling of the cells, leading to type 2 diabetes. These higher lipid levels also impair islet beta cell function, and with the insulin resistance, it aggravates hyperglycemia.[36] Women with BMI of 35 or greater had a 93 times higher risk of developing diabetes than those with BMI of less than 22.

Obesity also increases the risk of high blood pressure, or hypertension, which is characterized in obesity-related cases by an increase in vascular volume, despite a borderline or slightly elevated peripheral resistance. Several mechanisms may be involved in the development of hypertension in obese people, including increased renal sodium and water absorption, sympathetic

nervous system activation, changes in Na^+/H^+-ATPase activity, and growth factor–mediated structural changes to the vascular wall. In each case, hyperinsulinemia, which is an excess amount of circulating insulin, may be a contributing factor. One study also shows that participants with BMI of 30 or greater were twice as likely to have hypertension compared to non-obese participants. Similarly, people with abdominal obesity, which is defined by a waist circumference of at least 102 cm for men or 88 cm for women, were twice as likely to have hypertension. This direct relationship between BMI, abdominal obesity and the risk of hypertension was evident among whites, African Americans, and Hispanics.[37]

Sleep apnea is when a person has one or more pauses in breathing or shallow breaths during sleep. This is caused by a partial or fully blocked airway while a person is sleeping.[38] Obesity can cause a collapse in the pharyngeal airway because it increases the soft tissue surrounding the airway, which narrows the size of the pharyngeal airway. Obesity, particularly central obesity, also increases visceral fat volume which decreases lung volume. A reduction in lung volume increases the collapsibility of the pharyngeal wall possibly because of decreased longitudinal tracheal traction. Since there is no neural compensation for these abnormalities during sleep as there is when the person is awake, pharyngeal obstruction can occur, as seen in Figure 11.[39]

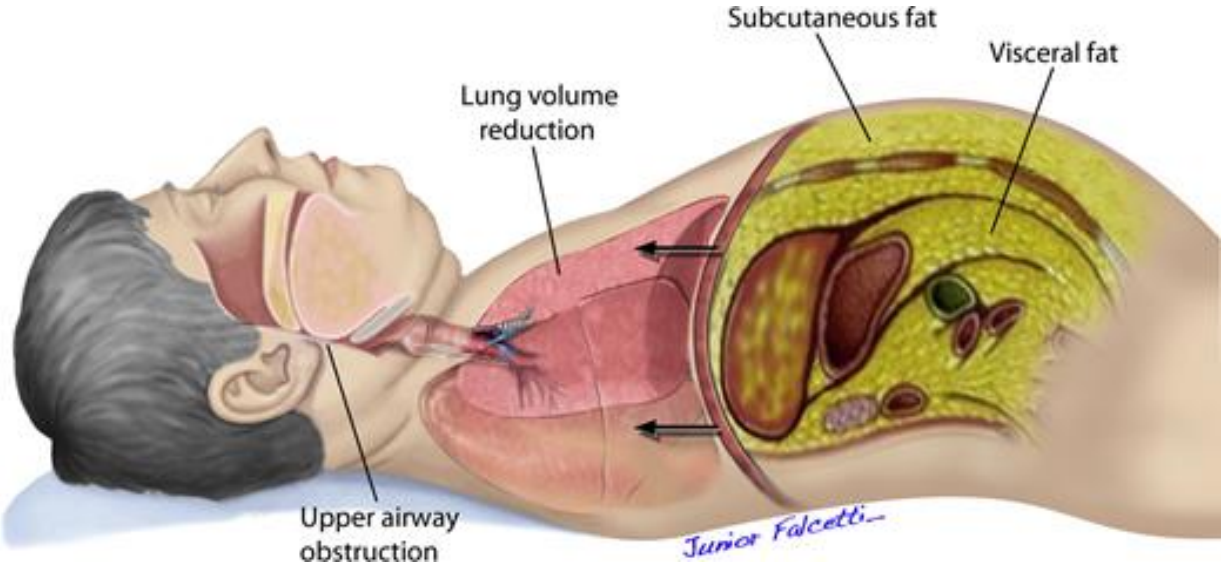

Figure 11: Pharyngeal obstruction[40]

Cholecystitis and Biliary Obstruction

Gallstones are formed when bile hardens due to excesses of cholesterol, bilirubin, or other bile salts.[41] These gallstones are usually asymptomatic unless they are very large, but contractions of the gallbladder may cause them to block the cystic duct, common bile duct, or entrance to the duodenum.[14] As the gallstone blocks bile release, components of bile such as bilirubin may accumulate in the surrounding tissues and cause jaundice, or yellowing of the skin. In the cystic duct, gallbladder contractions will become painful during digestion. In the duodenal opening, pancreatic enzymes as well as bile will be blocked and acute pancreatitis may occur, causing damage to the pancreas as well. Cholecystitis, or inflammation of the gallbladder, is usually the result of a gallstone blocking the cystic duct. This results in narrowing and scarring of the walls. Other signs of cholecystitis include pain or cramping along the right upper belly to the shoulder for extended periods of time, clay colored stools, fever, nausea, or vomiting.[42]

Biliary obstruction may also occur due to metabolic abnormalities in hepatic (liver) cells, such as hepatitis (viral infection), drug-induced cholestasis (slowing of bile production), biliary cirrhosis (chronic inflammation), or alcoholic liver disease. The growth of tumors in surrounding organs like the gallbladder or pancreas may compress the ducts as well.[43]

People who are overweight or have high cholesterol levels are at greater risk of developing gallstones, especially women due to the effect of estrogen removing cholesterol from blood and depositing it in bile. Those of Hispanic, Native American, or Northern European descent will have increased risk as well. Parasites common in Southeast Asia, like *Opisthorchis viverrini,* may also cause increased risk of bile duct diseases.[44] In the US, about 20% of the population over the age of 65 will develop gallstones and the reported incidence of gallstones is 1 million new cases per year. About 5 out of every 1000 people will develop a biliary obstruction.

When detected early, cholecystitis and other complications of a gallstone can be prevented through treatment. Infections have a very low mortality rate if treated promptly. Cholecystectomy is the most common treatment for cholecystitis and gallbladder cancer and usually results in full patient recovery if the tumor is small.[42] If the tumor has spread or is large, the survival rate falls.

Bile Duct Tumor (ampulla of Vater):

The ampulla of vater is at the intersection of the pancreas, common bile duct, and small intestine.[45]

Carcinoma of the ampulla of Vater often leads to biliary obstruction. This is a fairly rare form of gastrointestinal cancer. A picture of the anatomy can be seen in Figure 12, and it shows that the presence of a tumor blocks a major intersection of the bile duct, intestine, and pancreas.[46] About 65% of ampullary cancer cases, according to the Surveillance, Epidemiology, and End Results (SEER) program of the National Cancer Institutes, are due to adenocarcinomas. Carcinoma is the next most common histology at 8% and the third most common histology is a benign adenoma giving rise to the tumor in the ampulla of Vater. This adenoma, called a villous adenoma, should be removed as well to prevent future occurrences. Lymph nodes are also common sites of metastases in nearly half the patients. The liver, however, is the most common site of metastases. In advanced cases, lung metastasis may also occur.[47] When the bile duct is blocked due to a cancer in the ampulla of Vater, bile, and therefore bilirubin builds up. Bilirubin is a substance that is dark yellow and is secreted when old red blood cells break down. This is usually processed in the liver and then travels down the bile duct into the intestine. Afterward, it eventually exits the body through the stool (the body's solid waste). Bilirubin buildup can lead to jaundice, which is when the skin and eye whites turn yellow. Because there is such a noticeable symptom, ampullary cancer is often diagnosed at an earlier stage than pancreatic cancer.[48]

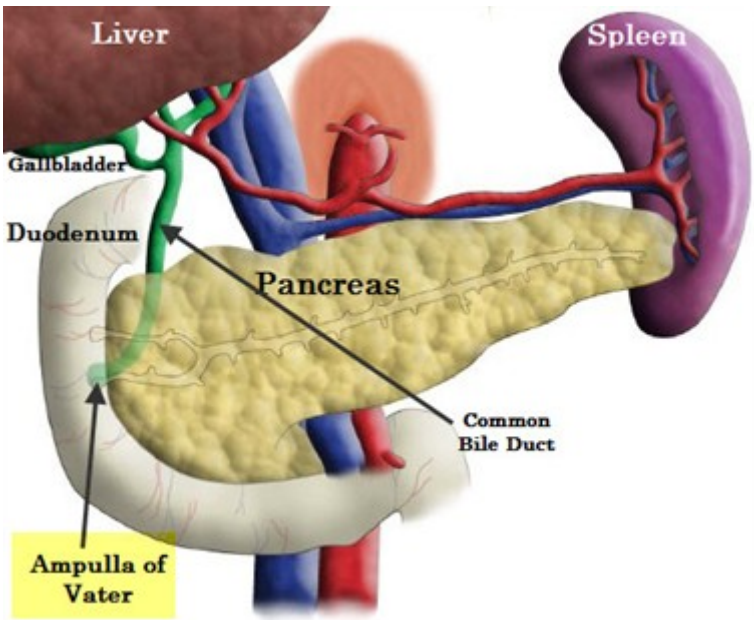

Figure 12: A cancer in the ampulla of vater can block secretions from both the pancreas and the bile duct (liver and gall bladder) into the small intestine, as can be seen in the diagram.[46]

The most common symptom is jaundice, but other symptoms may include nausea, vomiting, abdominal pain, weight loss, and fever.[48] Post-operative mortality rates are about 5% now, better than the during the 1970s when the mortality was much higher, around 25%. Morbidity rate is around 65%.[49]

II. TREATMENT OPTIONS & CURRENT STANDARDS OF CARE

Roux-en-Y gastric bypass:

Gastric bypass surgeries are performed on obese patients for whom nonsurgical methods of weight loss have failed. Roux-en-Y is a particular technique of gastric bypass surgery, which has two distinct benefits that contribute to weight loss. Roux-en-Y has become the gold standard of gastric bypass surgery, though a traditional Billroth and MGB techniques also exist. Seen above in Figure 13, the stomach is separated, the top smaller pouch is reconnected to the jejunum, and the bottom larger pouch is stapled shut. The result is a egg-sized gastric pouch that leads from the esophagus directly to the jejunum and a sealed section of the stomach still leading to the duodenum, forming the Y shape that gives the technique its name.[51,52]

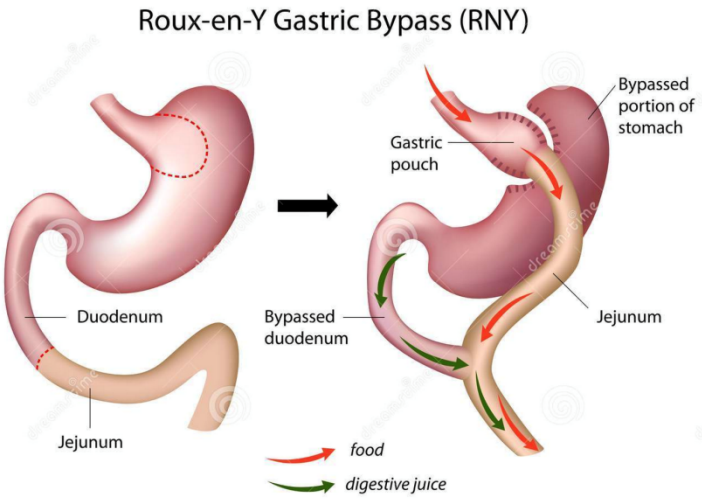

Figure 13: Roux-En-Y[50]

The main advantage of gastric bypass surgery is a smaller stomach, which leads to feeling full relatively quicker and thus eating less. This stomach is typically only 10% of the original size.[52] A second advantage of Roux-en-Y is that since the duodenum is significant to nutrition absorption, bypassing the duodenum causes reduced absorption of an already-reduced intake. Because of these advantages, Roux-en-Y is now the most common weight loss surgery.[53]

Roux-en-Y can be performed as either an open surgery or as a laparoscopic surgery, though surgeons are trending towards mostly laparoscopic methods.[53] Compared to open surgery, laparoscopic surgery generally has shorter hospital stays and quicker overall recoveries. [51] Laparoscopic surgery also relies on multiple small incisions, which tend to be cosmetically preferable over a single large incision. Additionally, laparoscopic surgery can be less painful and reduce the risk of hernias or infections.[51]

Patients who undergo Roux-en-Y, on average, lose more than half their excess weight. They stayed in the hospital for a median of 2 days, and returned to work 21 days after the surgery.[54]

Testing for biliary obstruction:

Testing for biliary obstruction may be done using laboratory tests and imaging. Several metabolic indicators are described here. Serum bilirubin is the most commonly used test because regardless of the cause of obstruction, bilirubin levels are usually elevated because of metabolic deficiency. Alkaline phosphatase (ALP) is almost always elevated as well, unless the obstruction is incomplete or intermittent. However, high levels are not specific to cholestasis and additional testing must be done to determine the exact cause. Elevated levels of antimicrobial antibody may indicate

whether primary biliary cirrhosis is at work, as opposed to mechanical obstruction, where levels are low.

Of the imaging methods, ultrasonography (US) is the least harmful and least expensive. Its accuracy for visualizing biliary obstruction is 95%. However, the cause and level of obstruction are not always determinable from US because the sonographic size range of the bile duct for each disorder is not consistent, bile duct stones cannot be seen, and visualization is less useful obese patients.[55] Computed tomography (CT) scans can overcome these factors because of the use of intravenous dyes that differentiate vasculature and the biliary duct. However, the contrast dye exposes the patient to radiation and is overall more expensive. A spiral CT scan can shorten the exposure time and improve resolution of the image by reducing artifacts from pulmonary activity. As bilirubin levels increase though, the ability to visualize and define the biliary tree and tumors lessens due to a decrease in blood flow and the dye carried by it. An endoscopic retrograde cholangiopancreatography (ERCP) may also be used to visualize both the biliary and pancreatic systems, using a combination of endoscopic and radiologic techniques. A cannula is advanced through the ampulla of Vater using endoscopy, then a contrast agent is injected to allow X-ray imaging. Corrective actions can be taken at the same time by placing stents and drains, and biopsies can be taken using a smaller scope. This method comes with considerable complications compared to the other methods, such as hemorrhage, sepsis, pancreatitis, and adverse reactions to the dye, but the risk is usually below 10%.[45]

Choledochojejunostomy:

When a patient presents with symptoms indicating a bile obstruction, a Percutaneous Transhepatic Cholangiography is performed to visualize the bile duct. A radio-opaque dye is inserted into the biliary system and pictures are visualized under fluorescence.[56]

If needed, a tube or catheter is used to set up a biliary drain to relieve the blockage in the duct, often as a temporary solution before surgery.

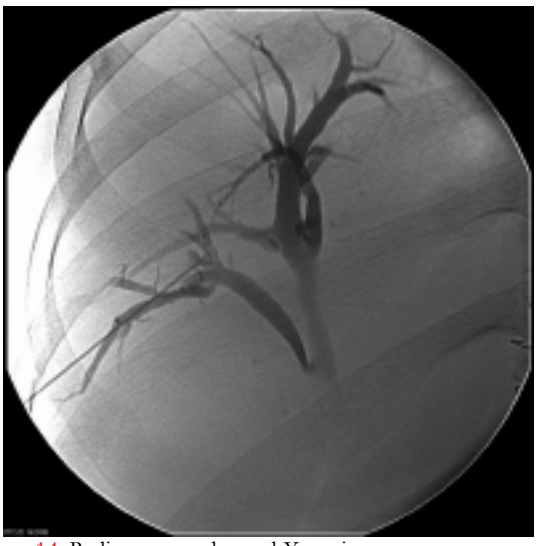

Figure 14: Radio-opaque dye and X-ray images are used to highlight the biliary ducts[57]

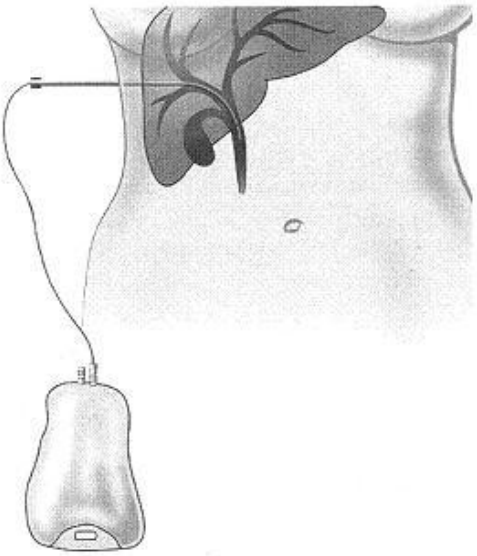

Figure 15: A catheter is inserted into the bile duct if there is an obstruction[59]

The surgery that is performed next is an exploratory surgery to determine if the obstruction is benign or malignant. A biopsy of a quickly frozen sample of the biliary obstruction is performed and results typically arrive within 15 minutes. Next, depending on the nature of the obstruction, a choledochojejunostomy is performed. A choledochojejunostomy is an anastomosis of the common bile duct to the jejunum as seen in Figure 16 on the next page. Three steps

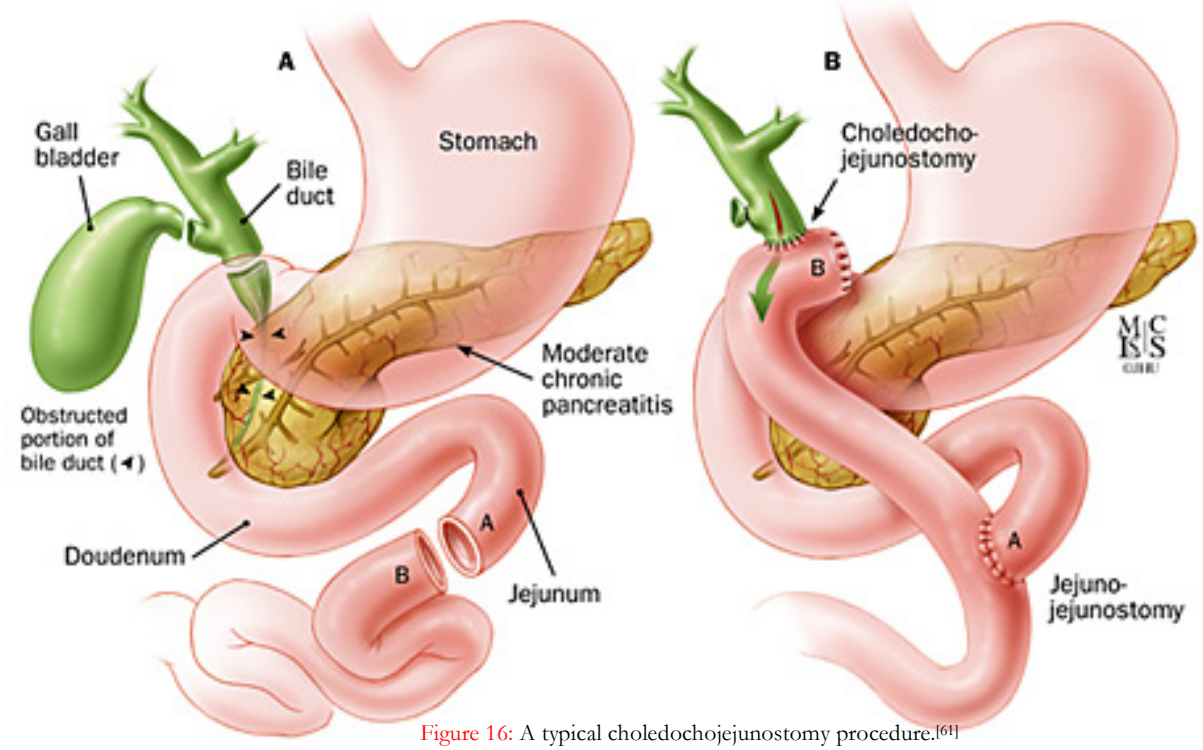

Figure 16: A typical choledochojejunostomy procedure.[61]

important to the surgery are exposing the duct, dissection of the obstructed region, and ensuring the biliary continuity.[60]

Dissecting the plane between the right lobe of the liver and the duodenum often reveals the biliary duct. Next, the duct is transected above the level of the obstruction. The most time intensive portion of the surgery is completing the alternating sutures that begin in each corner and are tied to the anterior wall of the anastomosis. Important for a proper anastomosis is ensuring that there is little tension between the mucosa-to-mucosa boundaries. This will ensure that there is no post-operative tearing and offers proper connection between the bile duct and the intestine.[60]

Ventral Hernia Repair:

Ventral hernia repair involves making a vertical incision, usually from the bellybutton to the tip of the sternum. The protruding mass is either returned to its original position or removed if necrotic, and the organs are adjusted into their proper position. The surgeons usually explore the surrounding tissue for signs of protrusion or weakness in the abdominal wall or for deleterious effects of the hernia formation. Afterwards, the abdominal wall around the mass is strengthened. Usually, extensive suturing is used to tightly shut the wall; sometimes, a mesh, typically made of either synthetic carbon fiber or biomaterial such as pigskin, is placed over the tissue and sewn into the abdominal wall for additional support. The surgeon may also sew the herniated tissue into place to prevent future protrusions.[62] In the case of herniated tissue that has been strangulated, blood and nutrient flow into the tissue is cut off, and the tissue becomes necrotic. In the case of strangulated intestinal, chyme flow is blocked, and bleeding into the abdomen can occur. Thus, the ventral hernia becomes life threatening, and emergency surgery is called for to remove the necrotic tissue and perform anastomosis on the healthy tissue.

Untreated hernias can grow, with more and more of the mass protruding out of the abdominal wall. Very large ventral hernias require a special procedure called progressive pneumoperitoneum,[63] in which the abdominal cavity is slowly expanded preoperatively to lower complications in hernia reduction. Doing so helps reduce the risk of abdominal compartment

syndrome, in which the contents of the hernia placed back into the abdomen can place a large amount of pressure on other bodily compartments, leading to ischemia (restriction of blood supply to tissues) or organ failure (due to mechanical trauma).

Inguinal Hernia Repair:

Treating inguinal hernias follows the same principles as a simple ventral hernia repair. The surgeon makes a transverse incision near the groin and pushes the protruding hernia tissue back into the abdomen. Either by extra suturing or by mesh, the surgeon reinforces the tissue around the hernia protrusion site.

Laparoscopic Hernia Repair:

While open surgery is required for repairing large hernias, laparoscopic surgery can be applied to smaller hernias. In such a case, the surgeon makes three to four smaller incisions and cannulates them. Small instruments can be inserted through the cannulae to insert the small protrusions back into the cavity and to introduce mesh for wall reinforcement. Laparoscopic procedures can reduce post-surgical complications and recovery time; however, they are not appropriate for large hernias or protrusions into the pelvis where previous surgery has occurred.[64]

Laparoscopic colectomy:

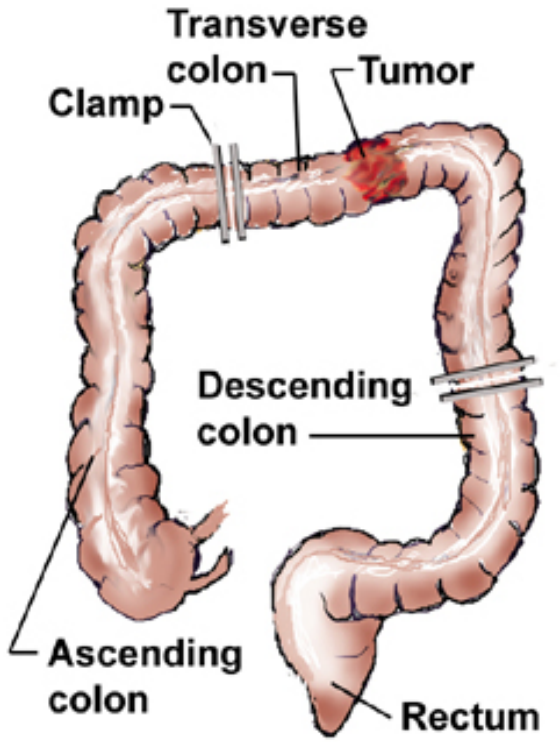

Figure 17: the laparoscopic colectomy procedure[66]

A colectomy is a surgical procedure done to remove all or part of your colon. A colectomy is done to remove disease causing symptoms such as cancer, polyps, irritable bowel disease, bleeding, blockage, diverticulitis, volvulus, and rectal prolapsed.[65]

First, to reduce the probability of infection and to prepare for the for the operation, the abdomen is inflated with CO2 to increase the working space and incisions are made for the laparoscopic instruments. Excess fat within the working area are cleared so that the target of interest within the colon are identified and marked. Then the abdomen is deflated and a small incision is made to reveal the area of interest. The colon is brought out and then potentially harmful specimen is clamped using surgical staplers and removed. The surgeon then reconnects the two ends of the colon, and closing sutures are done.[67]

Whipple procedure (pancreaticoduodenectomy) to remove tumor in ampulla of Vater:

The Whipple procedure, first performed and reported on by Dr. Allen Oldfather Whipple in 1935, is an extensive surgery used to remove tumors (benign or cancerous) within the head of the pancreas, duodenum, bile duct, or ampulla of Vater. The procedure involves removing the gallbladder, the head of the pancreas, the duodenum, and a section of the common bile duct

regardless of the location of the tumor to ensure negative margin (by removing connecting area and associated lymph nodes). A portion of the stomach may also be removed depending on the surgeon, although it is less common today.[68] In our case, the patient had a cancerous tumor in the ampulla of Vater blocking the entire bile duct.

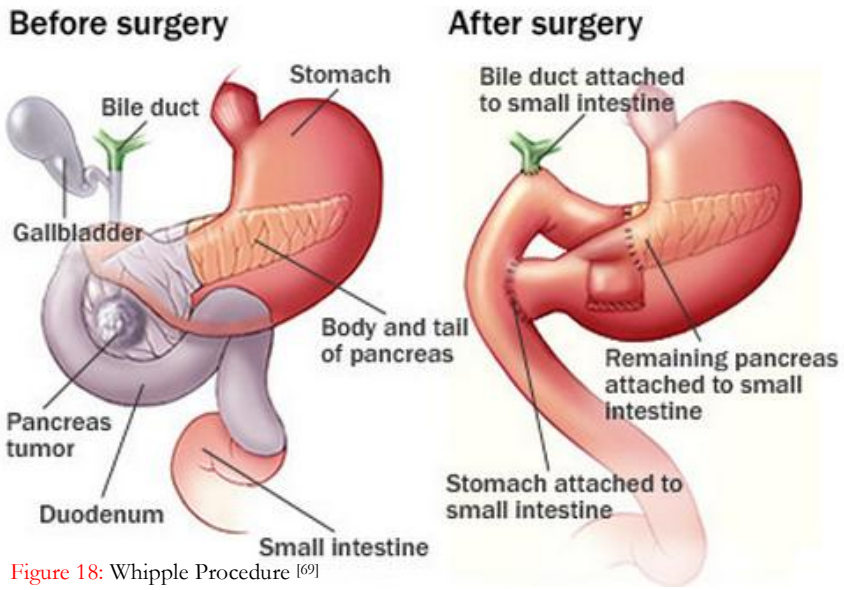

Figure 18: Whipple Procedure [69]

The Whipple procedure begins with the removal of the gallbladder. The respective connecting bile duct is sealed off. The main section of the common bile duct, connecting to the liver, gallbladder, and duodenum is then tied off and also removed. The head of the pancreas and the duodenum are stapled off from the rest of the pancreas and the small intestine respectively, and the entire section is then removed. The remaining section of the pancreas must then be sutured and connected via stent to the small intestine. The liver and stomach are also reconnected individually to the small intestine to ensure digestive processes are not blocked. Drains must be placed in the patient afterwards to clear out any leakages from the pancreas as it begins to heal.[68]

To completion, a typical Whipple procedure takes 6-12 hours. In order to adequately monitor the patient's vitals as well as administer drugs, a central IV must be inserted via internal jugular to the heart. While this IV is high risk for infection as well as technically difficult to insert using only ultrasound for vision, it is required for Whipple as it gives a definitive real-time blood pressure reading and allows more caustic drugs to be safely administered as the drugs will be more dilute in the heart than if injected in a vessel.[69]

The operation can lead to some immediate and long-term complications. Gastroparesis (stomach paralysis) can occur for a few days after the procedure as the stomach slowly adjusts to the changes. As stated, mild leaking from the pancreas can happen since the pancreas is a very soft organ, but rarely does it need to be re-operated on. In the long-term, patients may experience malabsorption of nutrients as the smaller pancreas is producing less enzymes to break down food.[68,69]

III. STAKEHOLDER ANALYSIS, OBSERVATIONS & PROBLEM IDENTIFICATION

Stakeholders:

1. Patient and their family

The patient undergoing the surgery is most directly affected by the procedure and its outcomes. Ideally, the surgery is minimally invasive and accomplishes the task at hand. Sometimes, the patient may need to make lifestyle changes, such as following gastric bypass surgery. Other things of importance include minimal risk of infection, minimal complications, and quick recovery time.

Families must provide emotional, social, and financial support for the surgery as well as the days leading up to and following the surgery. Sometimes, there are costs associated with complications that arise from the operation as well. The patient ideally does not want to wake up mid-surgery, and also hopes to wake up without any uncomfortable sores from bad positioning of the body during surgery.

2. Surgeons

The surgeons performing the surgery are the ones making decisions on the spot. They are most concerned with the details of the procedure as well as ensuring that the patient can survive past the surgery. The surgeon must be careful of excess bleeding, damaging peripheral nerves and major blood vessels, and make note of where all major organs should be or how they are connected. In addition, the main surgeon has the responsibility of teaching all the residents and medical students who are present, as well as ordering the various tools needed for the operation.

3. Residents, fellows, scrub nurses, anesthesiologists, other OR personnel

The residents are training to become surgeons themselves, so they are concerned with learning about the anatomy of the lower abdomen as well as the various techniques needed to undergo surgery. This includes knowing all the tools used, and how to improvise if needed. The scrub nurses are in charge of maintaining the sterile field and for providing the surgeons with all the tools as they are needed or anticipating them ahead of time. The anesthesiologist is required to maintain homeostasis during the entire surgery, which usually involves various IV drips and also sometimes a central IV for real-time blood pressures. Other OR personnel such as the circulating nurse are in charge of calling for various tools that are not already in the OR room, handling non-sterile objects, and also for keeping track of counts for things such as gauzes and needles. Most of the OR personnel are rotated out after several hour shifts; all except the main surgeon and the attending surgeons. They need a break and also to fill in their replacement every time they switch.

4. Hospitals

Hospitals are responsible for providing patients with pre and post-operative care. In addition, they house the instruments used during surgery and also profit from the various operations that take place each day. They are also concerned with image so sometimes there will be filming crew present in the OR for public relation purposes. Hospitals need to make sure all the procedures are sterile, and provide the facilities to sterilize all surgical tools in a central processing unit.

5. Insurance Companies

Insurance companies are concerned with various factors, including but not limited to cost and success rate of the surgery. They decide how much to pay and also how much to charge the patient for the surgery.

6. Medical Companies

These companies provide the tools that surgeons use during the operation. This may include biological tools such as drugs and IV drips, as well as mechanical tools such as the staple gun and cauterizer. They are responsible for troubleshooting the device in case of failure during the surgery, and also providing assistance in how to use the complicated instruments based on what the surgeon is trying to accomplish. The medical companies sometimes send representatives to the OR in order to observe, troubleshoot, demo, and occasionally provide free samples. They are interested in making their technologies better than the current standard of care, as well as obtaining FDA approval so that their products can be used in the US. Some companies also have a global audience so they must seek approval from various other countries that use different regulatory systems.

Introduction to Site:

The UCSF Department of Surgery is comprised of seven divisions: Adult Cardiothoracic Surgery, General Surgery, Pediatric Cardiothoracic Surgery, Pediatric Surgery, Plastic & Reconstructive Surgery, Transplant Surgery, and Vascular & Endovascular Surgery. Their surgeons provide care at four major hospitals in San Francisco: UCSF Medical Center at Parnassus, UCSF Medical Center at Mt. Zion, San Francisco General Hospital and Trauma Center, and San Francisco VA Medical Center.[70]

Introduction to Host: Hobart Harris, M.D.-MPH:

Dr. Hobart Harris is the Chief of the Division of General Surgery, Vice-Chair of the Department of Surgery, a Professor of Surgery at UCSF, and a Principal Investigator in the UCSF Surgical Research Laboratory at the San Francisco General Hospital. He is an expert in treating surgical infections and diseases involving the pancreas and biliary system. His research focuses on surgical infections, innate immunity and inflammatory diseases of the pancreas. Dr. Harris earned his medical and public health degrees at Harvard University, and then completed his internship and residency in surgery at UCSF. He then completed his fellowship in hepatobiliary surgery at the University of Hong Kong, Queen Mary Hospital before joining UCSF in 1994. Dr. Harris is currently a fellow of the American College of Surgeons as well as a member of several surgical and scientific societies including the American Surgical Association.[71]

Summary of Visits:

Suzzane & Derek

After a significant amount of trouble figuring out logistics, we finally arrived at the correct OR where a patient was being prepped. Two medical students, Andrew and Kartik, explained basic OR protocols and that the patient would be undergoing a massive ventral hernia repair. The patient had lost a large amount of weight to deal with obesity, and in the process had weakened her fascia so much it led to a massive ventral hernia. In order to repair the hernia, Dr. Harris first checked the contents of the GI tract before reducing them. Dr. Harris then used a biological mesh derived from pigskin, electing to use an overlay technique to reinforce the repaired hernia. Some doctors prefer underlay, though each doctor has their preference for a number of various reasons. Dr. Harris started working around 9AM, and was done around noon.

Because Dr. Harris' second surgery was scheduled for much later that day, we instead watched Dr. Carter perform a laparoscopic Roux-en-Y gastric bypass. In this surgery, a significantly smaller portion of the stomach is directly connected to the jejunum, while the rest of the stomach is stapled shut. This smaller stomach leads to feeling fuller more quickly, as well as reduced nutrient absorption as a result of skipping the duodenum. The surgery was quick, taking just over two hours, and left only small incision marks.

Helen & Sahithi

Both operations that were performed during our visit occurred in OR 28 under the supervision of Dr. Harris. A nurse named Susan gave a brief but helpful introduction to the operating room itself while the room was being set-up by a circulating nurse, Jason, and the scrub tech, Manny. The first operation was the removal of infected sutures from a previous surgery in obese female. This operation was performed by Brian, a new doctor, and Amanda, the anesthesiologist. No obstacles occurred during this procedure and we were able to see clearly using the lifts located in the operating room. The entire procedure lasted from about 8-8:30AM.

The second surgery was scheduled for 9AM, but set-up did not begin until around 9:30AM. Just prior to entering, we were instructed on how to properly put on face masks by Ben Friedman, a 3rd year medical student. The surgery was performed mostly by Natalie, a chief resident, and both she and Dr. Harris wore surgical headlights, while Natalie wore a surgical magnifying glass loupe as well. The patient was an older male with a blocked biliary duct. The initial incision was an upside down V-shape made on the abdomen, using a scar from a previous surgery as a guide. Once the biliary duct was found and a tissue mass detected, a frozen section biopsy was performed by the Pathology team to determine the nature of the sample. The mass was determined to be abnormal but benign, so Natalie proceeded to perform a choledochojejunostomy by removing portions of the common bile duct and intestine, then performing an anastomosis. The rejoining of tissue was the most time consuming part, requiring careful tracking of sutures and equipment. This surgery was much more time intensive, taking nearly 7 hours, and was more difficult to see because there were more staff involved and periodic rotations of the clinical staff.

Adrian & Vinay

The first surgery we witnessed was an abdominal hernia repair surgery. We were able to get incredibly close to the sterile field (without breaching it) while watching the surgery. The entire operation process took approximately two and a half hours, in addition to prep time and delay of two hours. This surgery was an open chest surgery in which the patient was opened to expose the condition. In addition to the hernia repair, Dr. Harris drained and examined the stomach fluid for a cystic condition that had the possibility of developing into a tumor. Samples of the stomach fluid and excess skin were sent to the lab for further diagnosis. The surgery concluded with the addition of a polymer mesh placed along the lining of the chest wall prior to closing sutures. The purpose of the mesh is for the bod to recognize it as foreign and as a result naturally produce another layer of tissue on the mesh.

For the sake of time, Vinay and Adrian decided it would be most worth it to witness separate surgeries: Adrian witnessed the laparoscopic colectomy and Vinay witnessed the inguinal hernia repair. The laparoscopic colectomy was a surgery that used traditional laparoscopic instruments - not automated systems such as Intuitive Surgical's da Vinci machine. The surgeon used small incisions for instrument placement to explore the cavity and identify targets. She then removed the instruments and made another incision to expose the targets on the colon. After cutting out the target tumor section, the med students examined it and sent it to the lab for diagnostic testing as she reconnected the two closed ends of the colon and concluded the surgery.

During the inguinal hernia repair the surgeon makes a transverse incision near the groin and pushes the protruding hernia tissue back into the abdomen. Either by extra suturing or by a wire mesh, the surgeon reinforces the tissue around the hernia protrusion site.

Toan & Vivian

Upon arriving at the surgical ward and changing into scrubs, we were directed into the operating room (rm 2) by a nurse and introduced to the two chief resident surgeons for the day, Dr. Eveline Shue and Dr. Jack Harbell, as well as the rest of the staff who were busy prepping the patient with a central IV line to the heart. The process took over an hour to finish, at which point Dr. Harris arrived to the operating room. As preparations concluded the scrub nurse announced the patient and the procedure to be performed. A Whipple procedure was to be done for the patient, who had a cancerous tumor in the ampulla of Vater and was suffering from jaundice.

Dr Harris, along with the two chief residents began with an incision down the chest of the patient and setup the point of focus using a series of retractors. The retractors were set up in order

to keep the abdomen open. The gallbladder was identified and removed first. Med student Ben Friedman took the removed gallbladder and cut it open to inspect for gallstones. The chief residents followed the bile duct from the gallbladder to the duodenum and removed a section of the bile duct after tying off the connecting vessels. The three surgeons proceeded to use an use an automatic stapler to clamp off and cut the end of the duodenum and the head of the pancreas. The entire connecting section was removed and opened to inspect the tumor. A swab of bile was taken for sampling. Finishing the removal of the large section, the staples in the other half of the pancreas were removed and a stent was placed in as the pancreas was attached to the small intestine. The stomach, liver, and bile duct were additionally attached to the small intestine at individual sites. Drains were added near the pancreas to ensure clearance from leakages and the patient was closed with sutures at the tissue layer and staples on the skin.

The surgery concluded after 8 hours. Dr Harris made closing remarks and answered questions as the rest of the staff finished the cleanup process and tool counting.

IV. UNMET NEEDS STATEMENTS, NEEDS FILTERING, PRIORITIZED LIST

Observations	Problem	Primary Need
There were people constantly moving and pushing carts around. Carts in the hallway had to be moved oradjusted to allow for larger carts or beds to move through.	Potential traffic congestion because shared between multiple ORs.	Operating floor hallway logistics are streamlined and organized.
The reception desk was crowded with many people trying to see where they needed to go.		
The phone right next to substerile door creates traffic		Operating floor hallways can allow for efficient transport of patients and equipment
Patient beds barely fit in the hallway		
A resident was texting with the same gloves he used to examine the patient.	PPE protocol is tedious and can hinder movement.	While wearing PPE, the clinician can use personal devices without contaminating either.
Putting on some masks "takes practice" and is "not intuitive." Masks have a face-shield attached, and tend to become hot. It was uncomfortable to breathe in the same air repeatedly. Masks can cause eyeglasses to fog up		PPE can support proper movement within the OR.
Staff members must put on new masks every time they enter the OR, but dispensing of masks not sterile		PPE can be quickly worn.
		PPE can be disposed in a sterile fashion.
Disposable scrubbers are used to clean hands/arms. Bristles get under the nails and any small spots. Few people use the finger pick available.		Scrub room tools are widely used to sanitize the hands and fingers and remove transmissible infectious agents.
When surgeons (residents, attendings, the occasional medical student) scrub in, other people have to assist them		Surgeons can properly scrub in alone.

Foot covers are mainly used to protect shoes from blood		The procedure effectively disinfects the portion of the surgeon's body in closest quarters to the surgical field.
Surgeons must hold their hands in front and above the waist as their hands are considered sterile after scrubbing		
Sterile gloving prodedure involves the surgeon reaching his/her hands into outstretched (in order) gown, then into two successive pairs of gloves.		
Sterile equipment is only handled by sterile gloves		
The sterile field is clearly marked.	Setting up sterile field is time consuming and requires precise positioning	The sterile field can be set up quickly.
Several drapes are used to mark the sterile field and to isolate the incision site in the surgical field.		The sterile field uses a minimal number of resources for setup.
Everything but the area of interest on the patient is covered.		
Scrub nurses expressed an interest in a visually-detectable signal for when scrubs or drapes are no longer sterile or are contaminated		Scrub nurses have objective evidence of whether the sterile field has been breached or contaminated.
Air is not filtered or sterile in the OR.	Maintaining maximum sterility in the OR is preferred, but not always possible	Maintenance staff actively ensure that shared resources and facilities on the operating floor remain sterilized.
During the surgery, the room smells overwhelmingly of burnt flesh from the electrocauter		
Plastic prevents skin from breaking and adds sterility.		
The door that leads into the hall can cause contamination. Staff are only supposed to enter substerile first, but the hall door was opened once during the operation.		
The Central Processing Unit in every hospital is responsible for collecting, sterilizing, and redistributing all tools. The CPU provides set kits for each surgery that are kept in boxes until scrub tech begins counting		
The door that leads into the hall can cause contamination. Staff are only supposed to enter substerile first, but the hall door was opened once during the operation.	Maintaining sterility is difficult during operation	Hallways and rooms on the operating floor are structured to maintain the sterile environment in the operating rooms.
The packaging that tools come in is not sterile and must be opened by the tech, but only the scrub nurse can take tools from opened package (2 people are required to get one new tool).		The scrub nurse can alone open the surgical tools in a sterile fashion.
The ultrasound machine came in through the main OR door instead of the substerile		Large machines for the operating room can maintain the sterility of the room.
The circulator did not know the number for the lab so Dr. Harris had to ask med student to look for it in his cell phone	Surgeon needs assistance doing non-sterile things from others	Facility ergonomics take into account sterile and other practices common to the

Some staff use the button pressed with the hip/knee to turn the sink on, while others use the foot pedal.	Using hands to operate facilities is unsterile and inconvenient	OR
All doors can be opened with a button. No one pushes doors manually.		
Some staff use the button pressed with the hip/knee to turn the sink on, while others use the foot pedal.		
Patient charts can be misplaced when the patient is wheeled in for surgery.	Chart misplacement jeopardized patient identification and case confirmation	Identification of patient, case, and special needs is ensured upon patient arrival into the operating room.
Before each surgery, attending physicians verbally confirmed patient and case, along with important allergies and special procedures.		Critical identifying information remains with the patient at all times.
All supplies must be adequately stocked.	Keeping track of materials and supplies in the OR requires great organization and still leaves room for error. Staff can sometimes be inattentive and misplace or forget something.	Clinicians in the OR are aware of the status of supply stocks for surgery.
The circulator called for a number of different carts, but they did not arrive until surgery had already started.		
Sterile nurses lay out instruments in a certain fashion on the sterile table to track the state of equipment used in surgery.		
Clinicians would like all instruments to remain within the sterile field and not slip out.		
Clinicians expressed interest in a "wireless headcount" that tracks all devices kept in the field.		Surgical supplies are systematically organized and tracked.
Surgeons thought they had lost a tool, and paniced a bit		
The team used white boards to update any new items used in surgery (lap pads, sutures), but sometimes the circulator had to rely on their memory.		
The white board is used to keep track of sponges, gauzes, tools. Numbers are added next to the tool as more are used, and no numbers are ever erased until the end of surgery.		
Needles are all counted and stuck in needle box. Nurses counted multiple times because the numbers did not add up.		
The substitute scrub tech did not know where everything was as well as the first scrub tech		
Nurses have to manually scan in all used laps (sterile rags)		
During surgery, nurses use a barcode scanner to track the bloody gauze used during each surgery, keeping count of each piece used.		
A needle fell on the floor towards the end during suturing, and everyone stopped to look for it		
Ongoing counting of suturing needles by hand ensures that none are left inside the patient.		

Needle fell on floor during surgery towards end during suturing up so everyone stopped to look for it		
Bottle of albumin was empty for a while before replaced (pressure caused bubbles to form)		
Surgeons needed to remember exact order of the clamps, thread		
Forgot Tachosil, might not be a big deal		
Surgical tables are manually adjusted by cranking. The first OR room had a creaky, poorly working crank.	The scrub table is uncomfortable to use and fairly primitive	The scrub table is easily adjustable for all user body types.
The current method of scrub table height adjustment can damage fingers.		
Nurses expressed interest in a pneumatic, pedal-operated height adjustment of the scrub table		
Sterile nurses lay out instruments in a certain fashion on the sterile table to track the state of equipment used in surgery.		
Setting all the tools needed out on the table takes a very long time, and only one person is allowed to do it during prep.		
The short scrub tech had to awkwardly reach surgical instruments on sterile instrument table. The aller scrub tech had to avoid hitting her head on the surgical light.		
The sterile table was cluttered with tools and containers stacked on top of each other.	There is not enough space on the operating room tool table.	The tool table adequately holds all tools and containers in an organized fashion
SED machines were not set up by the time the patient arrived from pre-op.	Set-up times can extend surgery and also delay following surgeries	OR prep for surgery is consistent and organized
Setting all the tools needed out on the table takes a very long time, and only one person is allowed to do it during prep.		
Delays in getting patients ready for the OR can cause surgical pileups and rushing.		
Maneuvering carts took a while pre-surgery. Around 7 carts in the first operation and took about 10-15 minutes to set everything in a convenient place.		
Prep time took from 7:30AM to around 9AM. An epidural was injected during this time.		
The OR was too small and not designed well for efficient space usage, despite being redone within the last year	OR space is cramped and not efficient	OR space is ergonomically organized.
Cords all along the floor make it hard to maneuver tables and carts around the room		
The needle delivering the local anesthesia leaked a bit onto the skin of the patient	Lots of materials go to waste	Supply waste is minimized

Because of fears of contamination, most materials in the OR are single use. This results in a lot of waste.		
A patient required 14 days of insufflation in order to stretch the abdomen prior to hernia repair.	Patient must undergo uncomfortable pre-op procedures to prepare for surgery - results in patient compliance issues	Pre-operative directions are followed
A patient clearly has not followed the prescribed diet. Following the diet would have made surgery easier and reduced the risk of complications.		
Staff are often unsure of exactly where doctors are, or when they will be arriving.	Locating staff can be difficult	Communication between critical members of the surgical case assists with organization and completion.
Dr. Brian said he was not found on the doctor system, did not have a code yet		
The anesthesiologist spent a few minutes untangling tubes	Various wires and cords from machines are obstructive.	The equipment in the anesthesia bay can be well-organized.
The anesthesiologist and nurses complained about the large number of wires used for monitoring devices.		The layout of monitoring devices in the anesthesia setup efficiently uses cables and connections.
Cords all along the floor make it hard to maneuver tables and carts around the room		
The cord for the anesthesia cart was plugged really far away from table.		The anesthesia bay is close enough to the patient to allow for timely and appropriate intervention.
Guiding the arterial catheter into the arm requires isolating the artery, knowing how far to plunge the needle, and expertly threading the catheter tube through.	Catheter operation requires expert training and may result in blood loss	Cathether operation is intuitive.
		Catheter operation minimizes injury to the vessel in which it is inserted.
Current solutions to the aterial catheter guidance problem involve using a needle with several lateral openings such that blood gushes out of a hole based on how deep the catheter is.		Catheter insertion is low risk
A surgeon calibrates scopes on glasses using her thumbs	Much of prep is done manually by staff	Preparation of incision site is easy and refined
A marker is used to mark incision site and biopsy tissue		
The staff shave the operating site while the patient is on operating bed if necessary		
Staples for securing sterile area are used after the patient is sedated. They pierce the skin and must be removed with tweezers.		
A pressure alternating mattress prevents pressure sores for long surgeries	Long surgeries can cause circulation problems in sedated patients	The device prevents clotting in vital systems during surgery.
Air pumps help alternate pressure on the legs, allowing blood to circulate from the lower extremities during surgery		
To reduce blood clots, compression socks are given. This helps reduce the risk of DVT.		

Many hematostats were employed at same time, and sometimes a surgeon must hold several at once		The device prevents hemorrhage into the surgical field.
The staff shave the operating site while the patient is on operating bed if necessary	Preparation of incision site requires several steps	Disinfection of incision site is easy and refined
A marker is used to mark incision site and biopsy tissue		
Chloraprep alcohol solution is used to wash and clean skin of operating area		
Chloraprep is tinted orange, making it easy to see where it has spread		
Two packs of the disinfectants are used. Only one size is available		
Patient was semi-conscious during Chloraprep due to stinging on skin rash.		
A 3M "fake skin" layer is positioned over patient before incision		
Local anesthesia is administered around incision site using a needle		
A surgeon uses scissors to manually adjust opening in sterile field		
Cloths are stapled directly to the body of the patient.		
To observe if anesthetics have effectively paralyzed the patient, the clinician stimulates the ulnar nerve with different types of electrostatic potentials. Twitching of the thumb gives an indication of the neuromuscular block.	Unclear if anesthesia is active or not	The anesthesiologist can confirm the effectiveness of his/her drugs during the course of the surgery.
		Patient sedation is fully controllable throughout the entire surgery
Anesthesiologist has to be there to monitor stats at all times		An anesthetized patient' vital signs and stats can be easily and properly monitored over the course of surgery.
A wireless pulse oximeter would present an improvement in pulse oximetry technology.		
The patient woke up multiple times near the end of the surgery, and the doctor told the anesthesiologist that he felt breathing		The patient remains fully sedated throughout the entirety of the surgery
The central IV goes into the right internal juggular which can't be seen. An ultrasound required to insert the IV.	Central IV placement is difficult and risky	IV placement is intuitive and low-risk
Placing a central IV has a high risk of infection		
To keep patients restrained, cushioned, and warm during surgery; nurses and clinicians use several foam pads bound to the patient in order to keep him/her upon the operating table.	Loss of patient warmth is potentially life-threatening	The patient is kept warm throughout the surgery
UCSF does not have hug-u-vacs as seen at VMTH. Instead, lots of foam cushions are used.		
Patient warmth is an issue.		

Anesthesiologists need to prevent hypothermia during surgery because the patient's body is not regulating under anesthesia. They use bair huggers and plastic bags.		
During gastrointestinal surgery, whole organs are sometimes removed from the patient for surgical treatment or removal of certain segments. The risk of infection runs high.	Invasivity of procedures means high risk of infection	Risk of infection is minimized for open surgeries.
		Surgery can be performed on organs with them remaining inside the patient.
Smaller, leaner patients are much easier to open as they do not have as many layers of fat in the way.	Performing surgery on obese patients is more difficult and more risky	Surgery can be performed regardless of body type
Most of the patients for GI surgery are obese, which makes maneuvering during operations more difficult and causes more complications, despite the relative simplicity of some surgeries.		
Beds were not wide enough for some patients (e.g. patient's leg falling off table).	Adjustments to patient position based on size must be done with additional props	
UCSF does not have hug-u-vacs as seen at VMTH. Instead, lots of foam cushions are used.		Surgical equipment can easily adapt to anatomical differences amongst different patients
The mesh used must be manually resized for the body.	Certain tools are not sized properly for the patient	
There aren't specific tools for GI surgeries, and surgeons had to order some tools from the cardiac and liver transplant departments.	Not many tools are available to optimize how quickly or safely GI procedures can be performed.	Surgical equipment is well-suited for GI procedures.
For management of stomach cysts, the surgeons puncture the cyst with a needle, suture the cyst ends to the stomach wall and close up the stomach such that the cyst can drain into the stomach.		
Dr. Harris had to make a stent out of red rubber tubing to connect the pancreas to intestine	Surgeons have to sometimes improvise equipment at the operating room, bypassing benchmarking tests to ensure the safety of the equipment	
It would be helpful to have a stapler with a scalpel (normal) with an option to cauterize it as you staple -Dr. Carter	Stapler sometimes causes bleeding or does not seal completely	Stapling is effective and refined
		The device achieves complete anastomosis of tissue.
Electrocauters used for surgery (the "bovie") use radio-frequency waves to prevent stimulation of muscle and nerve tissue during cuts. Therefore, the tool can be used to cut through tissue or burn-ligate vessel without electrically stimulating tissue.	Ligation of tissue must not adversely affect the physiology of tissue.	The ligation device keeps the physiology of tissue intact and health
The curvature of the needle was frustrating to work with.	Instruments malfunctioned during surgery	Surgical instrument grip is comformtable in surgeons' grasps.
Clamps are hand bendable but requires strength		
Ligasure had problems with an awkward, rotating grip		

There was some blood and other materials stuck in suction for a while		Suction can maintain a complete and unobstructed airflow.
The suction vacuum is sometimes too strong		
Suction tubing was not set up properly. The tube was circled around rather than straight and should have been connected to the suction port on the other side of room. The surgeon had to pull on the tube to get enough slack.		
The forceps were very slippery and took a while to grasp tissue. Sometimes, the forceps were not the correct or proper size.		Instruments are quality-checked and have redundancies engineered in design
Tools must be sharp before use		
There was a bad pair of scissors that were not tested ahead of time		
Clamps were also being tested right before they were handed off to Dr. Harris		
The cauterizer machine failed mid-incision, requiring a restart of the machine while surgeons waited		Backup systems can respond effectively to instrument or device failure.
The needles/sutures/thread sometimes got tangled. Clamps and sutures were hanging off of the table		Suturing can avoid obstruction of instruments with each other.
Cauterizer cord kept interfering with movement		
Retractors are hard to set up, need to get in between wires, and stay away from sterile area	Retractors can hinder surgeons' progress in the surgical field.	Keeping the patient's abdomen open provides adequate clearance for surgeons to operation.
Retractors were in the way of the surgeons		
Surgeons must ensure that clamps are not digging into any organs.		The retraction system allows the procedure to progress safely.
Time to construct "house" for keeping retractors is lengthy and tedious	Set-up of retractor system is time consuming and difficult to adjust	Retractor system is simple to set up.
The "ring" (table mounted retractor system) takes some time to assemble, really bulky		
Adjusting or adding a retractor takes about a minute		
The surgeons use multiple retractor clamps to hold in place the sutures that anchor down the mesh	Retracting tools used are labor intensive and difficult to use	
The surgeon uses two hands on graspers to keep the skin retracted. The forceps were very slippery and took a while to grasp tissue		
Surgical retractors have a serated brace that holds the instrument at a certain width. Contracting the instrument is difficult.		Retractor system is easy to adjust.
The electrocauter is used to transfer electricity to other instruments, which could be dangerous	The electrocauter may be dangerous to use	Cauterizer is safe and effective to use
Chief resident had to exchange gloves because she burned it off with cauterizing tool		
The first surgeon was nervous, and their hands were		

shaking during the surgery		
Ligasure button could be pressed from the side, and putting it down tended to press button	The electrocauter may malfunction during surgery	The electrocauter is reliable and consistent throughout surgery.
The cauterizing machine failed mid-incision, which required a restart of the machine while surgeons waited		
The cart for power source (cauterizers, argon beam, etc) is large and obstructive	Some tools obstruct movement of surgeons and staff	Surgical devices provide adequate clearance for use.
surgeons are connected up to machine via optic cable making it hard to swap around		
tubing was not set up efficiently so he had to pull to get enough slack (it was circled around rather than straight, should've used suction on other side of room)		Surgeons can easily manipulate surgical tools.
retractors were in the way of the surgeons		
Cauterizer cord keeps interfering with movement		
The ligasure is short and very slow when cutting up big pieces of tissue	Use of some tools is not intuitive or uncomfortable	
"I feel like this Ligasure is too big for my hands" - Natalie		
Bovie tip rotating unintentionally ("Why is this thing spinning around?" - Natalie)		
Ligasure is short, very slow when cutting up big pieces of tissue		
Retractor slide-ons aren't intuitive and take some playing around with		
Camera for laparoscopy is hard to maneuver. Sometimes, when medical school students assist, they don't know what to do.		Tools to visualize the surgical field are easy to maneuver
Reducing the incision is one of the biggest priorities. Incision leaves muscular scar tissue, cosmetic scars.	Patients worried about aesthetic repercussions of surgery	Scarring is reduced as much as possible
Team is composed of attending (Dr. Harris), two assists, a scrub tech (nurse), and a rotating. The assists are typically residents or med students, the scrub tech runs the room and manages the sterile field. Rotating is not scrubbed in, gets whatever is needed in the room that isn't already there.	Training and teaching extends the time of surgery and may increase risk	Training and teaching is effective without impacting the surgery
Dr. Brian took a while to remove the staples from the skin and blue towel		
The first surgical resident was nervous, hands were shaking during the surgery		
Camera for laparoscopy is hard to maneuver and they sometimes have med school students do it and they don't know what to do		
A surgeon point-of-view video feed would be useful for nurses and for students observing the surgery.		
Dr. Harris changes techniques to teach residents and allow for practice (used cauterizer instead of stapler		

for a step		
Other staff come in during op to ask Dr. Harris for advice on cases		
Unsterile med student holding iPhone camera directly above the patient's surgery site to take a picture mid-surgery (under Dr. Harris' request)		
A surgeon point-of-view video feed would be useful for nurses and for students observing the surgery.	Viewing operation is difficult for students/observers	
Assisting people kept cracking their necks		
Stools are not always stable when stacked		
Chief resident had to exchange gloves because she burned it off with cauterizing tool	Supplies must often be replaced	Supplies are available and easily obtained
For especially bloody surgeries, clinicians need to have blood on hand in case of a transfusion		
Two or more staplers are sometimes needed, and in the first surgery, the circulator had to leave to room to get the second stapler		
Have to keep switching out the instruments into different ports		
Dr. Harris had to make a stent out of red rubber tubing to connect the pancreas to intestine	Obtaining new tools or calling for people is time consuming	Accessing previously unneeded materials is fast
The circulator did not know the number for the lab so Dr. Harris had to ask med student to look for it in his cell phone		
Some tools do not have extras prepared, it dropped surgeon has to use something else		
Packages tools come in are not sterile, must be opened by tech, but only scrub nurse can take tool from opened package (2 people required to get one new tool)		
not completely stocked with supplies, call as needed		
There aren't specific tools for GI surgeries, had to order some tools from cardiac and liver transplant		
The substitute scrub tech did not know where everything was as well as the first one	Rotations in staff required, but can lower efficiency	Rotating staff is seamless
Circulator doesn't know where some things are in this room		
Confusion when relaying biopsy order (nurse/scrub tech weren't sure of terminology)	Surgery time is extended by biopsy process and analysis of results	Biopsy and analysis is fast
Pathology processing of tissue samples during surgery can extend it, as the surgeon continues based on results		
Biopsy sample is delivered to path by someone who comes up to pick it from the OR - no automated delivery system		
frozen sections for biopsy can return results w/in 15-20 min		

All fluids into/out of patient are monitored to get a rough estimate of blood loss for post-op care	Fluids and vital signs must be tracked throughout entire surgery	Patient status is clearly and continuously monitored
Fans and suction are very loud in the OR when they are on which makes it hard to communicate to each other during the surgery. Everything has a fan (including headlamps) so there's a ton of noise pollution	Communication in OR is difficult due to noise pollution	Devices and machinery make only essential noises
communication between staff is critical		
Masks muffle speech and make hearing difficult		
stools are not always stable when stacked (nurse made loud sound once)		
Lots of loud beeping especially toward end of surgery		
Complaint from nurse about noise pollution. Suction, fans, lots of beeping, can make communication difficult at times.		
Tradeoffs between braided sutures (easier to tie, higher infection risk, usually absorbable sutures) and monofilament (harder to tie, less infection risk, usually permanent sutures)	Tradeoffs in ease of use and risk in suture types	Sutures are easy to tie and carry low risk of infection
Suturing with fingers is the gold standard in tissue joining	Suturing process is time consuming and labor intensive	
suturing is tedious and repetitive		
The needles/sutures/thread sometimes got tangled, clamps and sutures were hanging off of the table		
Scrub tech must rewet surgeons hands for each suture		
The curvature of the needle was frustrating to work with, could not use the straight needle		
Rolled-up gauze tied with suture twine is used in laproscopic procedures to soak up blood entering the operative field.	Fluids in the operative field obstruct vision	The operative field can be quickly cleared of obstructive fluids
Resident is advised to practice hernia repairs as much as possible to master the procedure by the end of July 2014	Learning curve for surgery is high	Resident can practice several hernia repair procedures regardless of patient case load
		Resident can track and gauge progress on performance in surgical procedures
The surgeon has tools suited for open surgery available in case laparoscopy fails or cannot solve the problem	Laparoscopy may fail due to human or procedural error during surgery	Laparoscopic tools are able to operate in compressed, constrained places of the anatomy.
The abdomen was inflated with CO2 before laparascope was inserted.	Laparoscopic proceudres require inflation and expansion of the abdominal site in order for surgery to begin.	
Exploratory laproscopic procedures determine the	Despite the use of a laparascope to	

area of interest prior to excision of target section in colon.	examine the tissue, open surgery was used to remove the colorectal cancer.	
After laparascopic exploration of the abdomen, the surgeons made an incision to remove the entire colon out ot the body for resection of the cancerous stretch and anastomosis of the colon stumps before reinsertion into the abdomen.		
The electrocauter produces fumes when used to cut open tissue or close off vessels.	Electrocauter fumes are distracting	The electrocauter prevents fumes from blocking the operative field.
Since the abdomen is in enclosed, using an electrocauter in a laproscopic procedure can fog up the field.	Viewing operative site in laparoscopy is difficult	The laproscopic camera can maintain an unobstructed view of the surgical field despite the use of other tools during the procedure.
The laproscopic lens is heated to prevent condensation.		
The OR has to be darkened to provide the best visualization of the operating field during a laparoscopic procedure	Laparoscopic viewing by camera is not optimal when room is bright	The endoscopic camera provides an effective view regardless of ambient lighting.
Gauze is more easily lost when used in a laparoscopic procedure.	Tracking gauze in the laparoscopic field can be difficult.	Laprascopically-inserted gauze can be easily retained and removed during the procedure.
Gauze is reused more often in laparascopic surgery than in open surgery, which can raise the risks for contamination and corss-organ transfer of celr		
Other staff come in during op to ask Dr. Harris for advice on cases	Surgeon may be distracted during surgery	Visitors to the OR can be attended to with minimal distraction of necessary staff.
		Visitors can enter the OR without causing intrusive infection.
The scrub nurse is sometimes far enough from the surgeons that he/she cannot just simply hand off instruments. A light toss is thus necessary.	Staff around surgeon needs to allow space for operation but remain close enough to assist.	The surgeons have easy and safe access to tools
		The scrub nurses observe space constraints around the surgeons
		Nurses and surgeons remain close enough to exchange tools and notes.
The suction vacuum is sometimes too strong	Suction strength cannot be controlled	The strength of the vacuum suction can be controlled.
The surgeons spend much time during procedures locating major vasculature so as to not injure them.	Surgeons can't easily visualize vasculature	The sources and destinations of sessels within the surgical field can be identified.
		Major vasculature in the surgical field can be visualized easily.
		Small or microscopic vasculature in the surgical

		field can be visualized easily.
	Injuring major vasculature can critically endanger a patient during surgery	Pre-operational planning accounts for avoidance of major vessels
		Surgical tools and procedures can leave major vasculature unharmed.
		The device can quickly heal unexpected injuries to the major vasculature.
Epidural anasthesia is in during the surgery and afterward, but it's just taped on so it becomes an issue when the patient moves or is moved during and after surgery	Tubes left in patient from a pervious operation obstruct movement during surgery	Epidural anesthesia lines remain in the patient despite movement.
		Invasive tubing within the patient prior to the first cut remains within the patient throughout the surgery.
		Pre-operative intubation of the patient is greatly simplified yet provides patients with essential anesthesia and monitoring.
		Patient intubation is compatible with surgical movements.
Drain from prior surgery needed to be moved and retied during operation		Drainage tubes in patient can be easily moved or reset throughout surgery.
		Post-operative staff observe proper drainage procedures after surgery.
Gauze is stuffed into the space between the muscular layer and the fascia to make room for the mesh	Mesh used in hernia repair may cause infection	Hernia repair mesh can resist infection.
For hernia repairs, overlay mesh gets infected more often while underlay does not, so a less reactive mesh would be good.		
The mesh must be soaked in antibiotics first		Methods to confine herniated masses into the abdominal cavity can prevent the recurrence of hernias.
When irrigating the cavity, blood and water spilled over to the flap on the side of the surgery table	Cleaning OR post-op is difficult	Surgical methods keep all bodily fluids within the surgical field.
Blood was covering the surgeon's gowns and parts of the floor		Post-operative cleanup ensures that bodliy fluids are properly disposed and kept away from causing infection.
Moving patient to the other bed is comfortable for	Transportation of patient is	Patient movement and

the patient	hindered by tubes and if the patient is large	transportation accounts for invasive tubing and bodily dimensions.
Scrub nurses and anesthesiologist able to rotate out to rest	Long surgeries require more labor	Long surgeries are manageable and comfortable for all.
Everyone but surgeons were rotated out		
Surgeon hands start to shake	Long surgery is physically draining for staff, especially for surgeons who can't rotate out	
Some surgeons also stood on one foot, shift weight		
Chief resident began forgetting names of instruments towards end of surgery, as she was extremely exhausted by the end.		
Chief resident complained to Dr. Harris about her and other colleagues being "so tired all the time"		
First surgeon was nervous, hands were shaking during the surgery	Ease of surgery affected by confidence/skill of surgeon	

V. ANTICIPATED IMPACT: MARKET ANALYSES

The gastrointestinal disease treatment market was valued at $49.9B in 2008, with the United States taking the largest market share at 37.8% ($18.8B).[72] This market reflects a very high level of generalization due to the nature, scope, and incomplete understanding of GI disease. These diseases can be contracted in a wide age range of patients with a multitude of symptoms. Tangible substances that add to the market include drugs that aim for treatment of peptice ulcer disease (PUD) and gastroesophageal reflux disease (GERD), and devices that aid in surgery such as the Intuitive Surgical da Vinci laparoscopic surgical system. In addition, companies involved in producing surgical materials such as sterile equipment manufacturers are key stakeholders in the space. However, many of the top ten pharmaceutical manufacturers saw a decline in sales over 2007, a fact indicative of the high level of generalization of GI disease. That being said, overseas in China and India the market for GI treatments are on the rise from $564M in 2012 to $784M in 2019, according to a new report by business intelligence provider GBI research.[73] It is said that the APAC region (Australia, India, China, Japan) is expected to see the most rapid market development - a rise of 7.7% during the forecasted period. However, the global GI market is expected to decline due to upcoming major patent expirations from $6.8B in 2012 to $6.6B in 2019. Cultural factors such as traditional herbal medicines make branded penetration of pharmaceutical drugs slow to grip markets. According to Obesity Coverage, "Of the three most popular bariatric surgeries (Lap Band, sleeve gastrectomy, gastric bypass), gastric bypass is the most expensive. Duodenal switch surgery and some revision procedures are usually the most expensive of all bariatric procedures, with the average price at $22k".[74] Obese patients are prone to developing complications where surgeries such as these may eventually become necessary, but studies show that the price of these surgeries did not fluctuate between 2013 and 2014.

VI. REFERENCES

1. "Your Digestive System and How It Works." *National Digestive Diseases Information Clearinghouse (NDDIC)*. U.S. Department of Health & Human Services, 18 Sept. 2013. Web. 10 July 2014. <http://digestive.niddk.nih.gov/ddiseases/pubs/yrdd/#what>.

2. "The Stomach (Human Anatomy): Picture, Function, Definition, Conditions, and More." *WebMD*. WebMD, n.d. Web. 07 July 2014. <http://www.webmd.com/digestive-disorders/picture-of-the-stomach>.
3. "The Stomach (Human Anatomy): Picture, Function, Definition, Conditions, and More." *WebMD*. WebMD, n.d. Web. 07 July 2014. <http://www.webmd.com/digestive-disorders/picture-of-the-stomach>., Krucik, George. "Stomach." *Healthline*. Healthline, 24 Apr. 2013. Web. 10 July 2014. <http://www.healthline.com/human-body-maps/stomach#seoBlock/1>.]
4. "Introduction to the Stomach (Digestive System)." *Stomach Anatomy*. N.p., n.d. Web. 10 July 2014. <http://www.ivy-rose.co.uk/HumanBody/Digestion/Stomach.php>.
5. *serosa*. Art. *Britannica Online for Kids*. Web. 10 July 2014. <http://kids.britannica.com/comptons/art-127643>.
6. "pepsin." *Encyclopaedia Britannica. Encyclopaedia Britannica Online*. Encyclopædia Britannica Inc., 2014. Web. 10 Jul. 2014. <http://www.britannica.com/EBchecked/topic/450873/pepsin>.
7. Purves, William K. "Why Don't Our Digestive Acids Corrode Our Stomach Linings?" *Scientific American Global RSS*. Scientific American, 20 Oct. 2003. Web. 10 July 2014. <http://www.scientificamerican.com/article/why-dont-our-digestive-ac/>.
8. Richard, Bowen. "Anatomy of the Stomach - Gastric Secretions." *About.com*. About.com, n.d. Web. 09 July 2014. <http://biology.about.com/library/organs/bldigeststomach3.htm>.
9. "gastrin." *Encyclopaedia Britannica. Encyclopaedia Britannica Online*. Encyclopædia Britannica Inc., 2014. Web. 10 Jul. 2014. <http://www.britannica.com/EBchecked/topic/226737/gastrin>.]
10. "Liver Anatomy and Function." *Health*. Loma Linda University, n.d. Web. 10 July 2014. <http://lomalindahealth.org/medical-center/our-services/transplantation/resources/liver-anatomy.page>.
11. "Normal Liver Physiology." *Biomed*. Brown University, n.d. Web. 10 July 2014. <http://biomed.brown.edu/Courses/BI108/BI108_2002_Groups/liver/webpage/Normal Liver.htm>.
12. "The Gallbladder (Human Anatomy)." *Digestive Disorders Health Center*. WebMD, 28 Apr. 2010. Web. 8 July 2014. <http://www.webmd.com/digestive-disorders/picture-of-the-gallbladder>.
13. "Anatomy of the Liver and Gallbladder." *SEER Training*. National Cancer Institute, n.d. Web. 8 July 2014. <http://training.seer.cancer.gov/biliary/anatomy/liver.html>.
14. Linder, Tom, and Anna Melby. "Regulation of Bile Release." *Conjoint 401-403*. University of Washington, n.d. Web. 8 July 2014. <http://courses.washington.edu/conj/bess/bile/bile.html>.
15. "Anatomy and Physiology of the Pancreas." *Www.cancer.ca*. N.p., n.d. Web. 15 July 2014.
16. "The Pancreas and Its Functions." Pancreas MD, n.d. Web. 17 July 2014.
17. "Physiology of the Pancreas." *TeachMeAnatomy*. N.p., n.d. Web. 18 July 2014.
18. "Small Intestine." *InnerBody*. N.p., n.d. Web. 09 July 2014. <http://www.innerbody.com/image_digeov/dige10-new3.html>.
19. "The Small Intestine." *The Lancet* 231.5983 (1938): 1006-007. Web.
20. "Small Intestine Diagram - JPG English_1607232790.ashx." *Foundation Level 4 Art Design Digital Sketchbook*. N.p., n.d. Web. 10 July 2014.

<http://sarahelizanwhc.wordpress.com/2012/10/22/identity-final-piece-ideas/small-intestine-diagram-jpg-english_1607232790-ashx/>.

21. "Nutrients Absorbed in the Duodenum." *Healthy Eating*. N.p., n.d. Web. 10 July 2014. <http://healthyeating.sfgate.com/nutrients-absorbed-duodenum-9610.html>.
22. The Editors of Encyclopædia Britannica. "Jejunum (anatomy)." *Encyclopedia Britannica Online*. Encyclopedia Britannica, n.d. Web. 10 July 2014. <http://www.britannica.com/EBchecked/topic/302416/jejunum>.
23. "Absorption in the Small Intestine." *Mind, Body, Science*. N.p., n.d. Web. 10 July 2014. <https://sites.google.com/site/mindbodyscience/biology/the-digestive-system/absorption-in-the-small-intestine---what-s-the-down-low-on-digestion>.
24. The Editors of Encyclopædia Britannica. "Ileum (anatomy)." *Encyclopedia Britannica Online*. Encyclopedia Britannica, n.d. Web. 10 July 2014. <http://www.britannica.com/EBchecked/topic/282743/ileum>.
25. Mayo Clinic Staff. "Colon Cancer: Symptoms." http://www.mayoclinic.org/diseases-conditions/colon-cancer/basics/symptoms/con-20031877, Last visited 7/15/2014.
26. Mayo Clinic Staff. "Colon Cancer: Risk Factors." http://www.mayoclinic.org/diseases-conditions/colon-cancer/basics/risk-factors/con-20031877, Last visited 7/15/2014.
27. Cappell, MC. "The pathophysiology, clinical presentation, and diagnosis of colon cancer and adenomatous polyps." Med Clin N Am 89: 1—42 (2005).
28. Polakis, P. "Wnt signaling and cancer." Genes & Dev. 14:1837-1851 (2000).
29. Gregorieff, A and Clevers, H. "Wnt signaling in the intestinal epithelium: from endoderm to cancer." Genes & Dev 19: 877-890 (2005).
30. MacDonald, Bryan T., Keiko Tamai, and Xi He. "Wnt/ -catenin signaling: components, mechanisms, and diseases." *Developmental cell* 17.1 (2009): 9-26.
31. Markowitz SD and Bertagnolli MM. "Molecular Origins of Cancer: Molecular Basis of Colorectal Cancer". N. Engl. J. Med. 361 (25): 2449–2460 (2009).
32. Giovannucci, E and Ogino, S. "DNA methylation, field effects, and colorectal cancer." Journal of the National Cancer Institute 97 (18): 1317–1319 (2005).
33. Anonymous. "Cancer Staging." National Cancer Institute at the National Institutes of Health, http://www.cancer.gov/cancertopics/factsheet/detection/staging, Last accessed July 15, 2014.
34. Jones, S et al. "Comparative lesion sequencing provides insights into tumor evolution." Proc Nat Acad Sci 105(11): 4283–4288 (2008).
35. "Gastric Bypass Surgery: Who Is It For?" *Mayo Clinic*. Mayo Foundation for Medical Education and Research, 6 Oct. 2011. Web. 10 July 2014. <http://www.mayoclinic.org/healthy-living/weight-loss/in-depth/gastric-bypass-surgery/art-20046318>.
36. Day, Caroline, and Clifford J. Bailey. "Obesity in the Pathogenesis of Type 2 Diabetes." *Medscape*. British Journal of Diabetes and Vascular Disease, 2011. Web. 10 July 2014. <http://www.medscape.com/viewarticle/745306>.
37. Pi-Sunyer, Xavier. "The Obesity Epidemic: Pathophysiology and Consequences of Obesity." *Obesity*. John Wiley & Sons, Inc., 6 Sept. 2012. Web. 10 July 2014. <http://onlinelibrary.wiley.com/doi/10.1038/oby.2002.202/full>.
38. "What Causes Sleep Apnea?" *National Heart, Lung, and Blood Institute*. U.S. Department of Health & Human Services, 10 July 2012. Web. 10 July 2014. <http://www.nhlbi.nih.gov/health/health-topics/topics/sleepapnea/causes.html>.

39. Isono, S. "Obstructive Sleep Apnea of Obese Adults: Pathophysiology and Perioperative Airway Management." *National Center for Biotechnology Information*. U.S. National Library of Medicine, Apr. 2009. Web. 10 July 2014. <http://www.ncbi.nlm.nih.gov/pubmed/19293689>.
40. Drager, Luciano F., Sônia M. Togeiro, Vsevolod Y. Polotsky, and Geraldo Lorenzi-Filho. "Obstructive Sleep Apnea: A Cardiometabolic Risk in Obesity and the Metabolic Syndrome." *Journal of the American College of Cardiology*. American College of Cardiology Foundation, 13 Aug. 2013. Web. 11 July 2014. <http://content.onlinejacc.org/data/journals/jac/927393/m_05045_gr1.jpeg>.
41. "Gallbladder." *Function, Location & Anatomy*. Healthline, n.d. Web. 11 June 2014. <http://www.healthline.com/human-body-maps/gallbladder>.
42. "Acute cholecystitis." *U.S National Library of Medicine*. U.S. National Library of Medicine, n.d. Web. 11 June 2014. <http://www.nlm.nih.gov/medlineplus/ency/article/000264.htm>.
43. Bonheur, Jennifer. "Biliary Obstruction ." *Biliary Obstruction*. Medscape, 5 Jan. 2012. Web. 10 July 2014. <http://emedicine.medscape.com/article/187001-overview#a0199>.
44. "Bile Duct Diseass." *Bile Duct Diseases Guide: Causes, Symptoms and Treatment Options*. Harvard Health Publications, n.d. Web. 10 July 2014. <http://www.drugs.com/health-guide/bile-duct-diseases.html>.
45. "Ampullary Cancer." *UCSF Department of Surgery*. N.p., n.d. Web. 10 July 2014. <http://www.surgery.ucsf.edu/conditions--procedures/ampullary-cancer.aspx>.
46. Kuwajerwala, Nafisa K. "Carcinoma of the Ampulla of Vater ." *Carcinoma of the Ampulla of Vater*. Medscape, 20 June 2013. Web. 10 July 2014. <http://emedicine.medscape.com/article/282920-overview#a0104>.
47. "Ampullary Cancer." *Center for Pancreatic and Biliary Diseases*. USC Department of Surgery, n.d. Web. 10 July 2014. <http%3A%2F%2Fwww.surgery.usc.edu%2Fdivisions%2Ftumor%2Fpancreasdiseases%2Fweb%2520pages%2FBILIARY%2520SYSTEM%2FAMPULLARY%2520CANCER.html>.
48. "Ampullary Cancer: Know the Signs of This Rare Disease." *Cancer Treatment Centers & Hospitals*. Cancer Treatment Centers of America, 8 Nov. 2013. Web. 10 July 2014. <http://www.cancercenter.com/discussions/blog/ampullary-cancer/>.
49. Kuwajerwala, Nafisa K. "Carcinoma of the Ampulla of Vater ." *Carcinoma of the Ampulla of Vater*. Medscape, 20 June 2013. Web. 10 July 2014. <http://emedicine.medscape.com/article/282920-overview#a0104>.
50. "Roux-en-Y Gastric Bypass Surgery." *Dreamstime*. N.p., n.d. Web. 18 July 2014.
51. "Roux-En-Y Gastric Bypass Surgery and Recovery." WebMD, n.d. Web. 18 July 2014.
52. "Roux-en-Y Gastric Bypass Weight-Loss Surgery." Johns Hopkins Medicine, n.d. Web. 17 July 2014.
53. "Roux En Y." *University of Maryland Medical Center*. N.p., n.d. Web. 17 July 2014.
54. Schauer, Phillip, Sayeed Ikramuddin, and James Lukeith. "Outcomes After Laparoscopic Roux-en-Y Gastric Bypass for Morbid Obesity." Annals of Surgery, Oct. 2000. Web. 17 July 2014.
55. Deitch, EDWIN A. "The reliability and clinical limitations of sonographic scanning of the biliary ducts." *Annals of surgery* 194.2 (1981): 167.
56. "Percutaneous Transhepatic Cholangiogram : MedlinePlus Medical Encyclopedia." *U.S National Library of Medicine*. U.S. National Library of Medicine, n.d. Web. 10 July 2014. <http://www.nlm.nih.gov/medlineplus/ency/article/003820.htm>.

57. "Percutaneous Cholangiography ." *EMedicine*. N.p., n.d. Web. 10 July 2014. <http://emedicine.medscape.com/article/1828033-overview>.
58. "Percutaneous Biliary Drainage ." *Medscape*. N.p., n.d. Web. 10 July 2014. <http://emedicine.medscape.com/article/1828052-overview>.
59. "Images Related to Biliary Drainage." *Cure Bytes RSS2*. N.p., n.d. Web. 10 July 2014. <http://trialx.com/curebyte/2012/10/21/images-related-to-biliary-drainage/>.
60. "Choledochojejunostomy ." *MedScape*. WebMD LLC, n.d. Web. 10 July 2014. <http://emedicine.medscape.com/article/1891439-overview#a15>.
61. "Choledochojejunostomy ." *School of Medicine: Gastroenterology*. Johns Hopkins, n.d. Web. 10 July 2014. <https://gi.jhsps.org/GDL_Disease.aspx?CurrentUDV=31&GDL_Cat_ID=AF793A59-B736-42CB-9E1F-E79D2B9FC358&GDL_Disease_ID=0ADCFD83-7DE7-4D53-82F5-6F0C9BFB7F14>.
62. UCSF Medical Center. "Ventral Hernia: Treatment" http://www.ucsfhealth.org/conditions/ventral_hernia/. Last visited July 10, 2014
63. Piskin, T et al. "Preoperative progressive pneumoperitoneum for giant inguinal hernias." Ann Saudi Med. 30(4): 317–320 (2010)
64. Mayo Clinic Staff. "Inguinal hernia: Treatment and drugs." http://www.mayoclinic.org/diseases-conditions/inguinal-hernia/basics/treatment/con-20021456 Last visited July 10, 2014.
65. "Laparoscopic Colectomy." *:: Center for Minimally Invasive Surgery*. N.p., n.d. Web. 11 July 2014. http://cmis.osu.edu/patient-care/colon/lapcolon/
66. "Http://www.yoursurgery.com." *Http://www.yoursurgery.com*. N.p., n.d. Web. 11 July 2014. http://www.yoursurgery.com/ProcedureDetails.cfm?Proc=17
67. "Colectomy." *What You Can Expect*. N.p., n.d. Web. 11 July 2014. http://www.mayoclinic.org/tests-procedures/colectomy/basics/what-you-can-expect/prc-20013604
68. "Whipple Operation." *Center for Pancreatic and Biliary Diseases*. University of Southern California, Department of Surgery, n.d. Web. 10 July 2014. <http://www.surgery.usc.edu/divisions/tumor/pancreasdiseases/web%20pages/pancreas%20resection/whipple%20operation.html>.
69. Venugopal, Roshni L., MD, Keith D. Grey, MD, and Kurt E. Roberts, MD. "Pylorus-Preserving Pancreaticoduodenectomy (Whipple Procedure) ." *Medscape*. N.p., 5 Mar. 2012. Web. 10 July 2014. <http://emedicine.medscape.com/article/1893199-overview#showall>.
70. "Clinical Excellence, Compassionate Care & Innovative Research: Taught by Example." *UCSF Department of Surgery*. The Regents of the University of California, 2014. Web. 12 June 2014. <http://www.surgery.ucsf.edu/>
71. "Clinical Excellence, Compassionate Care & Innovative Research: Taught by Example." *UCSF Department of Surgery*. The Regents of the University of California, 2014. Web. 12 June 2014. <http://www.surgery.ucsf.edu/>
72. "Strategic Growth Analysis of Gastrointestinal Market." *News-Medical.net*. N.p., n.d. Web. 10 July 2014. http://www.news-medical.net/news/20100121/Strategic-growth-analysis-of-gastrointestinal-market.aspx
73. "HomeMedia CenterPress ReleasesPharmaceuticals and Healthcare." *India and China's Gastrointestinal Treatment Markets to Witness Impressive Growth by 2019, Amid Peri| Pharmaceuticals and Healthcare*. N.p., n.d. Web. 10 July

2014.http://www.gbiresearch.com/pressreleasedetails.aspx?title=Pharmaceuticals_and_Healthcare&prid=277

74. "What's The Average Price Of Gastric Bypass Surgery? Our 2014 Survey | Obesity Coverage." *Obesity Coverage*. N.p., n.d. Web. 11 July 2014. http://obesitycoverage.com/insurance-and-costs/how-much/average-laparoscopic-gastric-bypass-prices